

# Diseases of the cervical spine

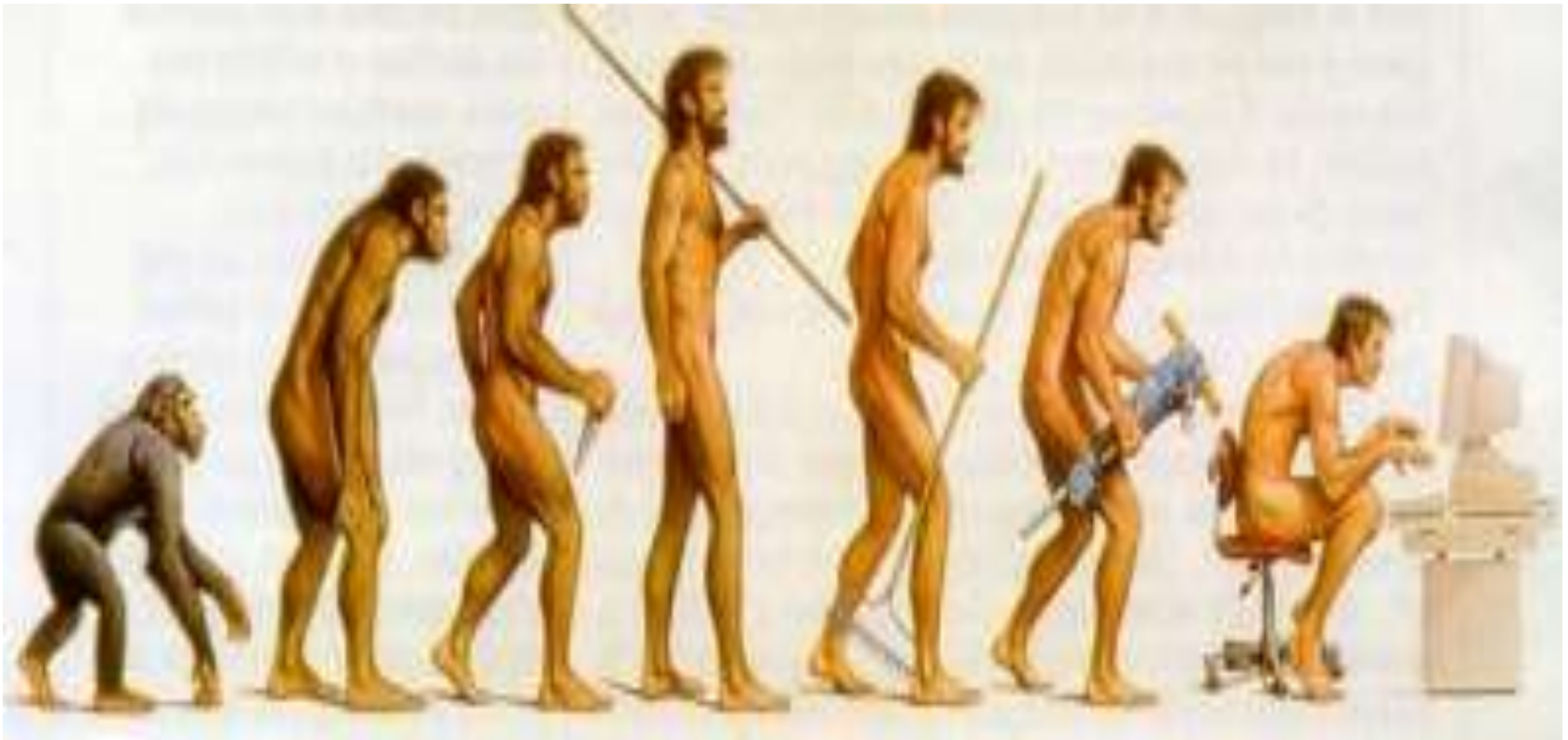
*Dr. Athanasios Giannakopoulos*

**Center for pain-therapy and spine surgery**  
Priv.-Doz. Dr. med. habil. Sebastian Ruetten

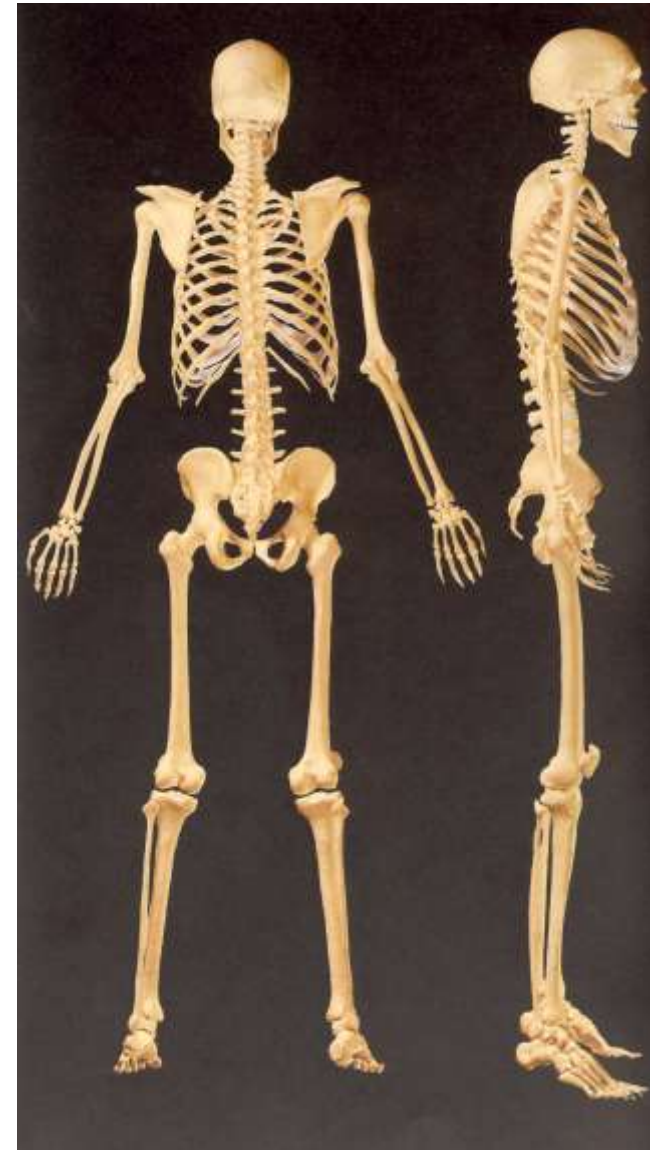

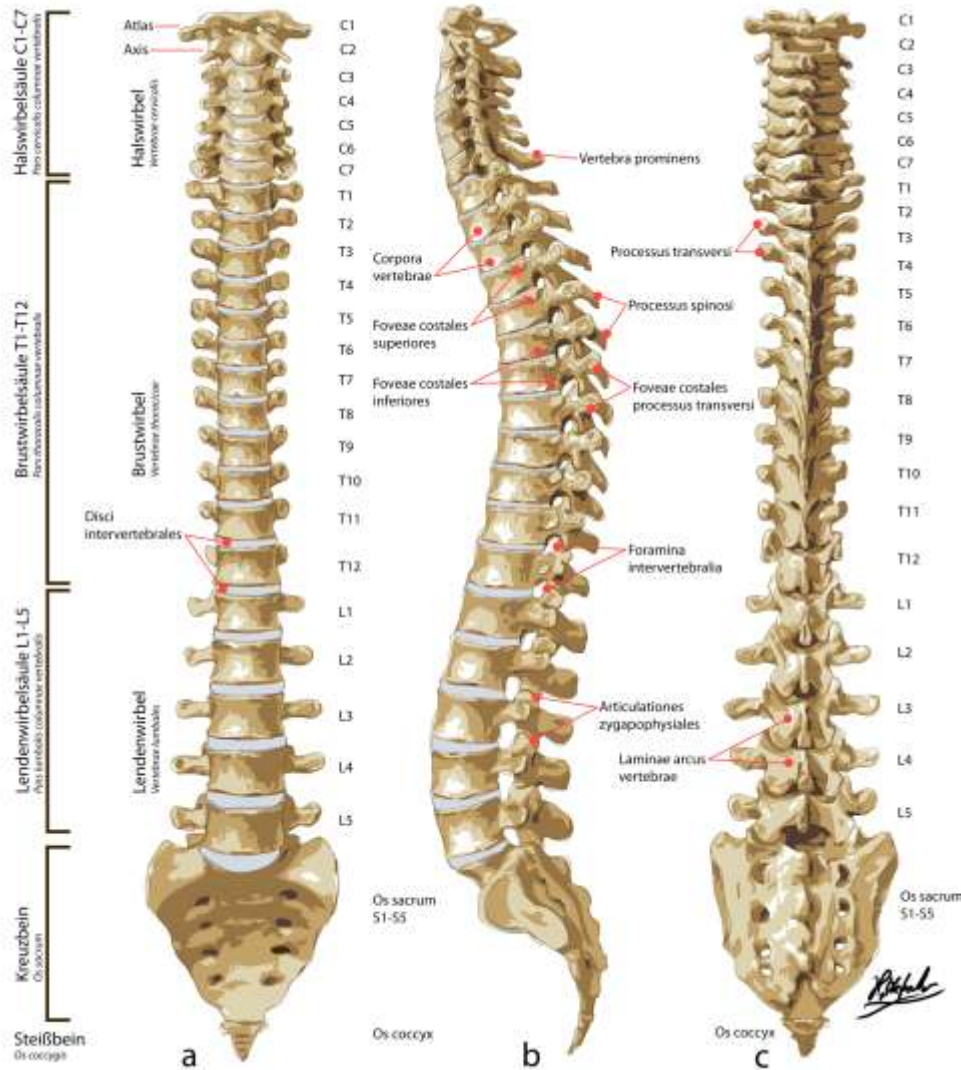**Center for orthopedic surgery and traumatology**  
**St. Elisabeth group**  
Director: Prof. Dr. med. Georgios Godolias

**St. Anna Hospital Herne**   
**Universitätsklinikum**  
**Marienhospital Herne**   
**Marien Hospital Witten** 



- Bearing structure for the head and extrimities
- Protects the myelon
- Bearing of the ribs
- Shock absorbing function



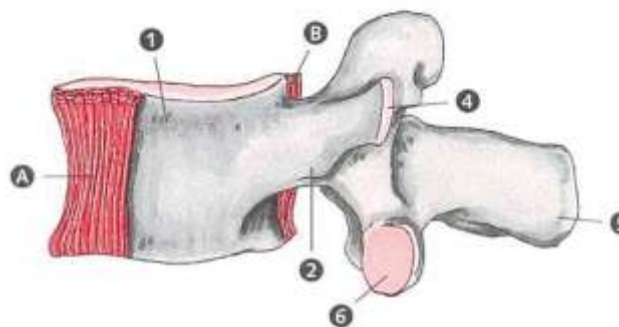
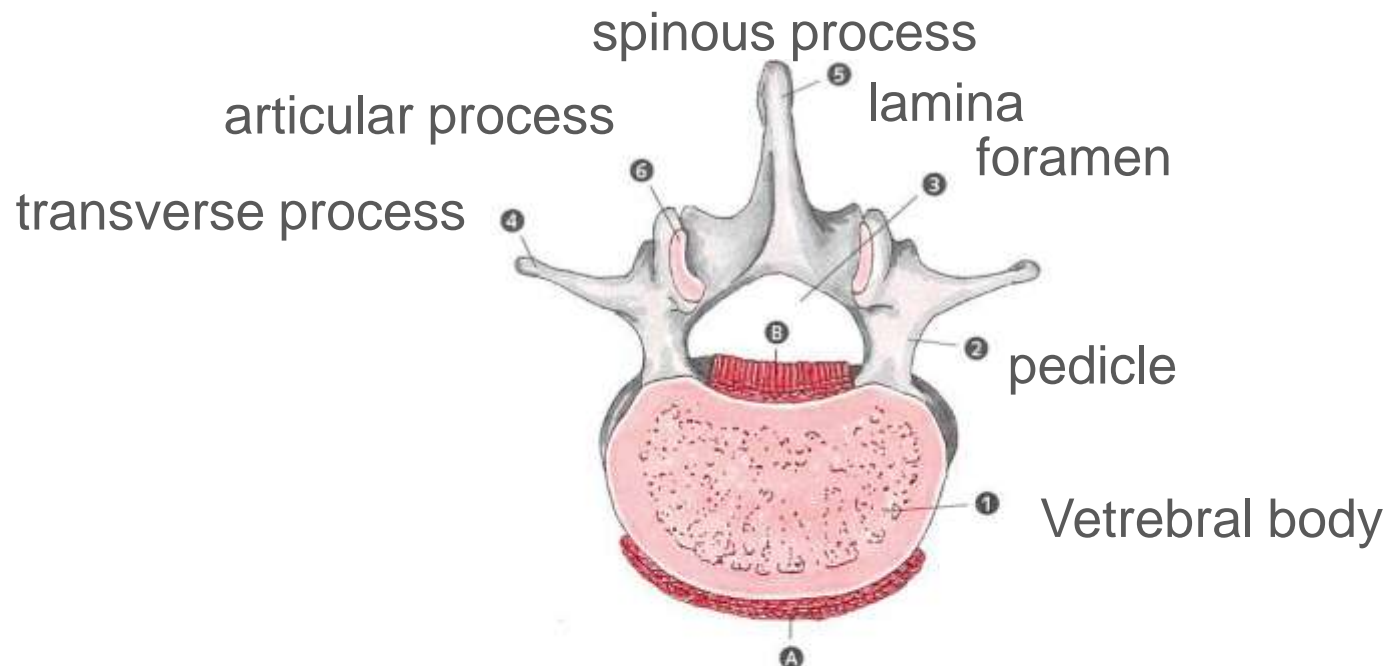


Cervical spine (7)

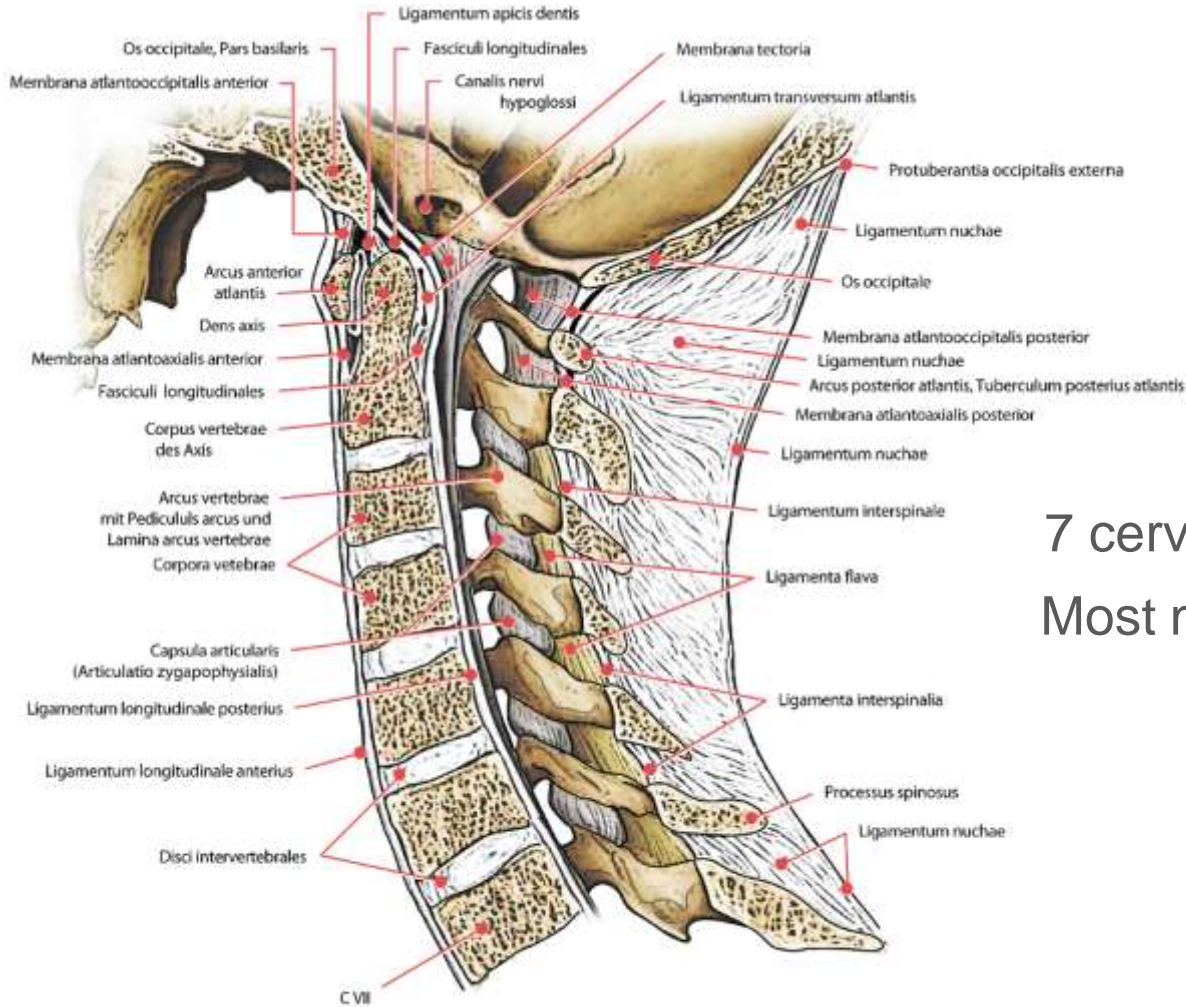
Thoracic spine (12)

Lumbar spine (5)

Sacrum (5)

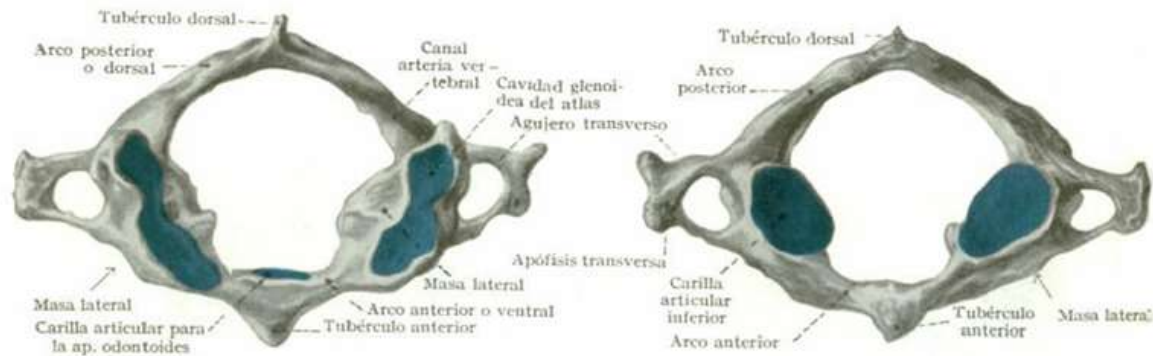






7 cervical vertebrae

Most mobile part of the spine

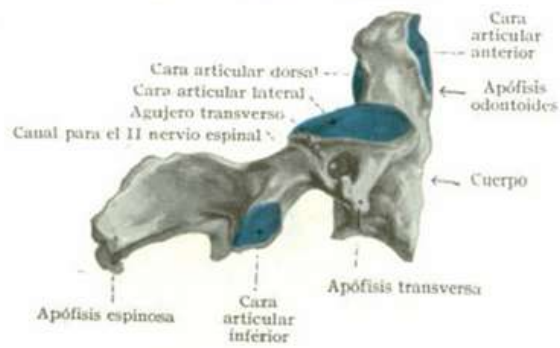


**Atlas**

Superficie craneal o superior

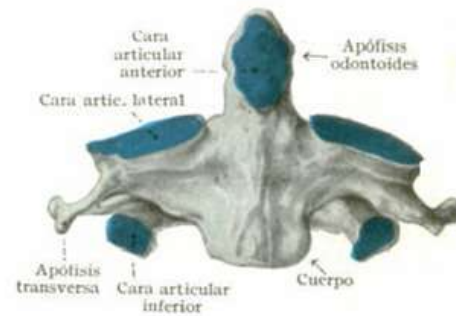
**Atlas**

Superficie caudal o inferior



**Axis (epistrophus)**

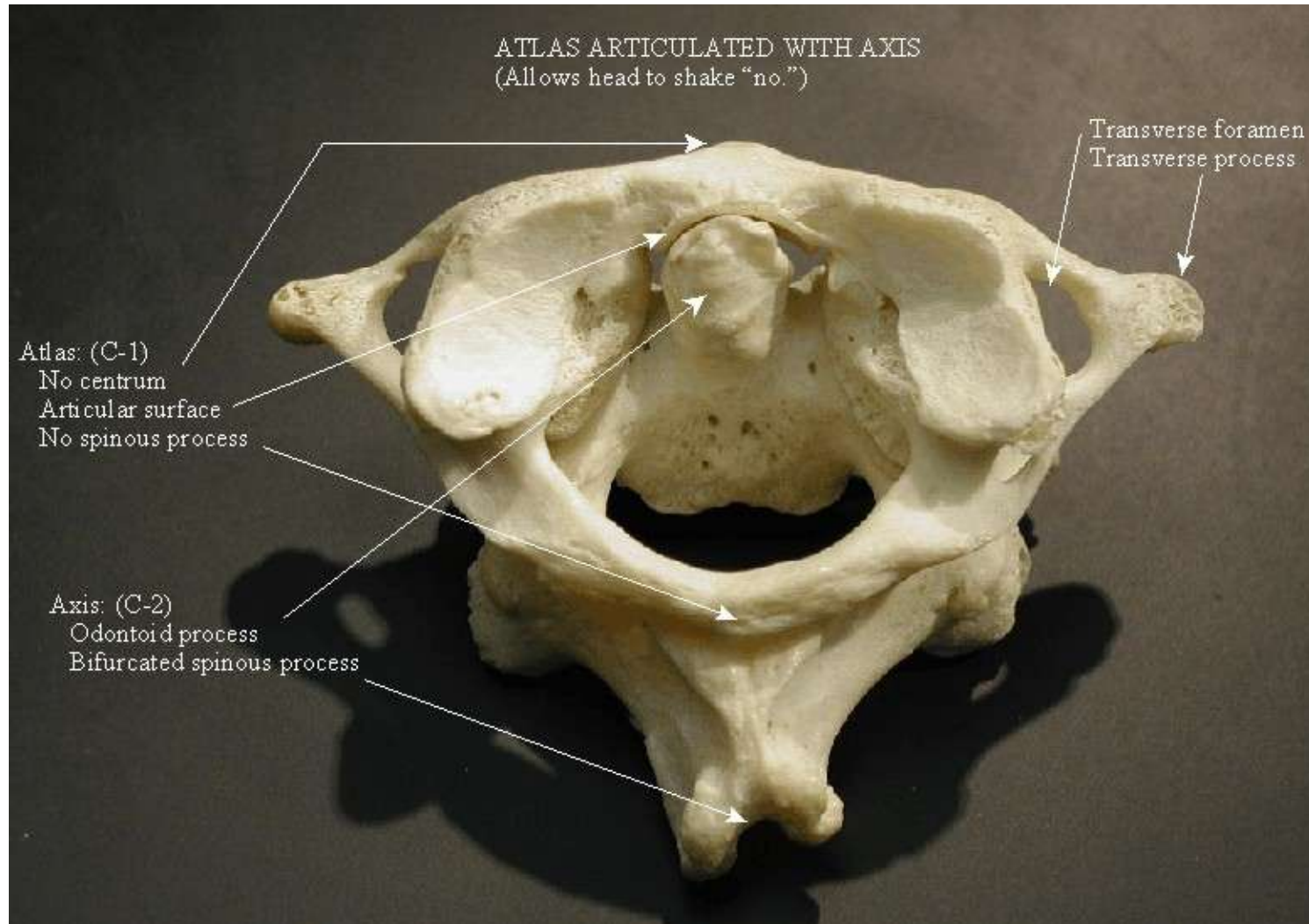
Lado derecho



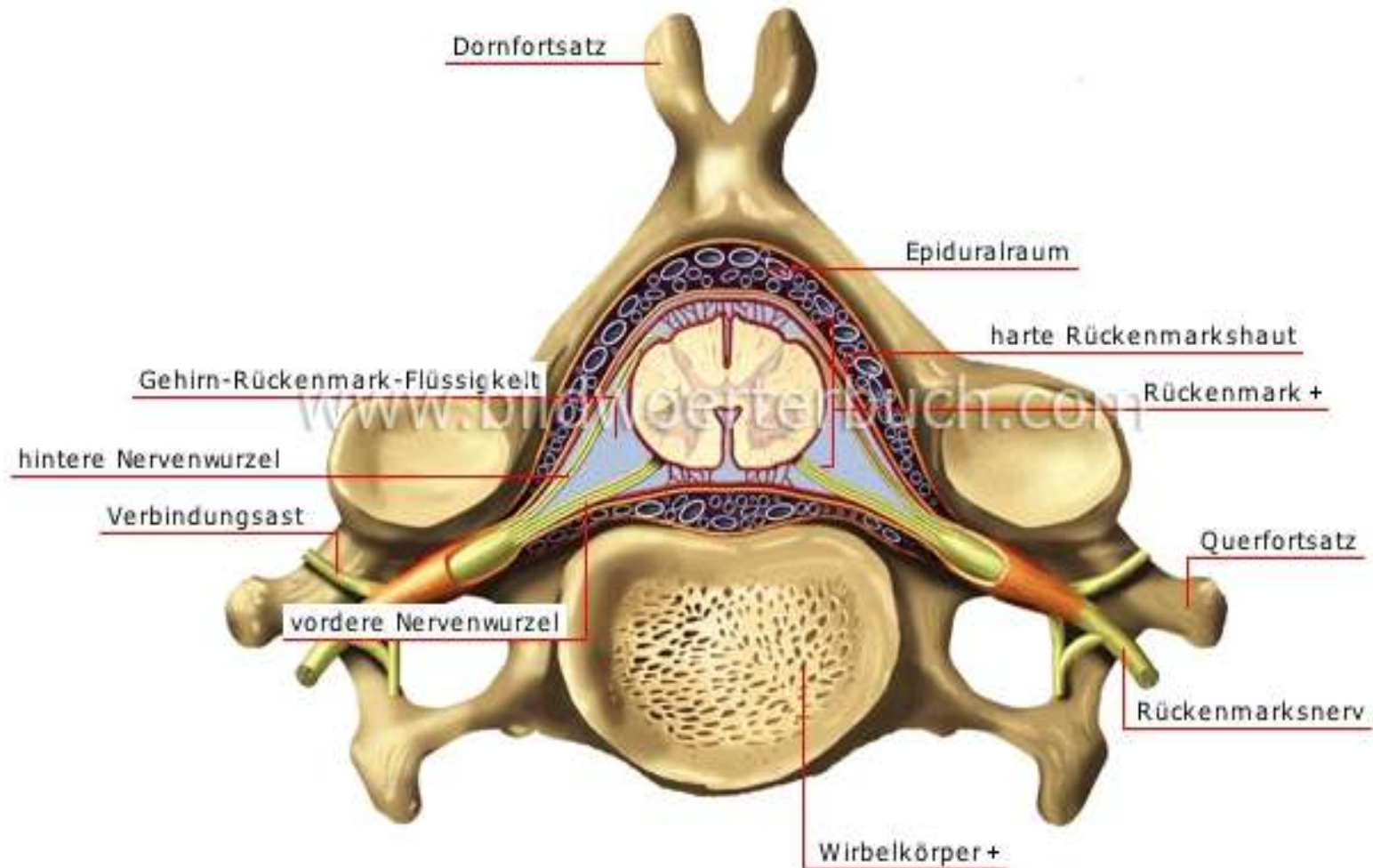
**Axis (epistrophus)**

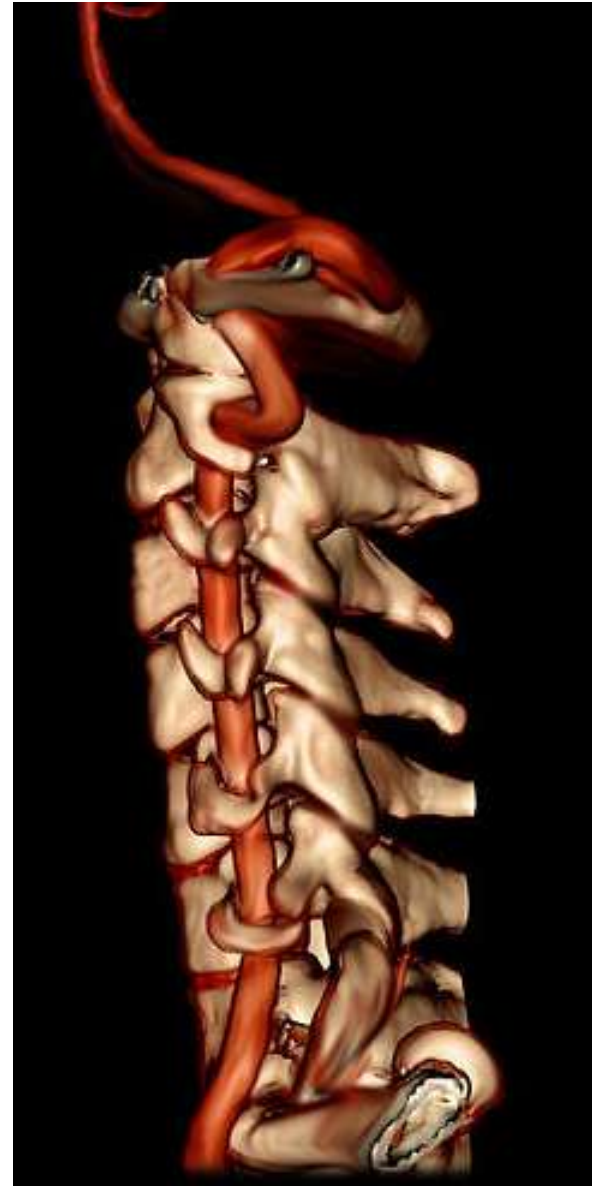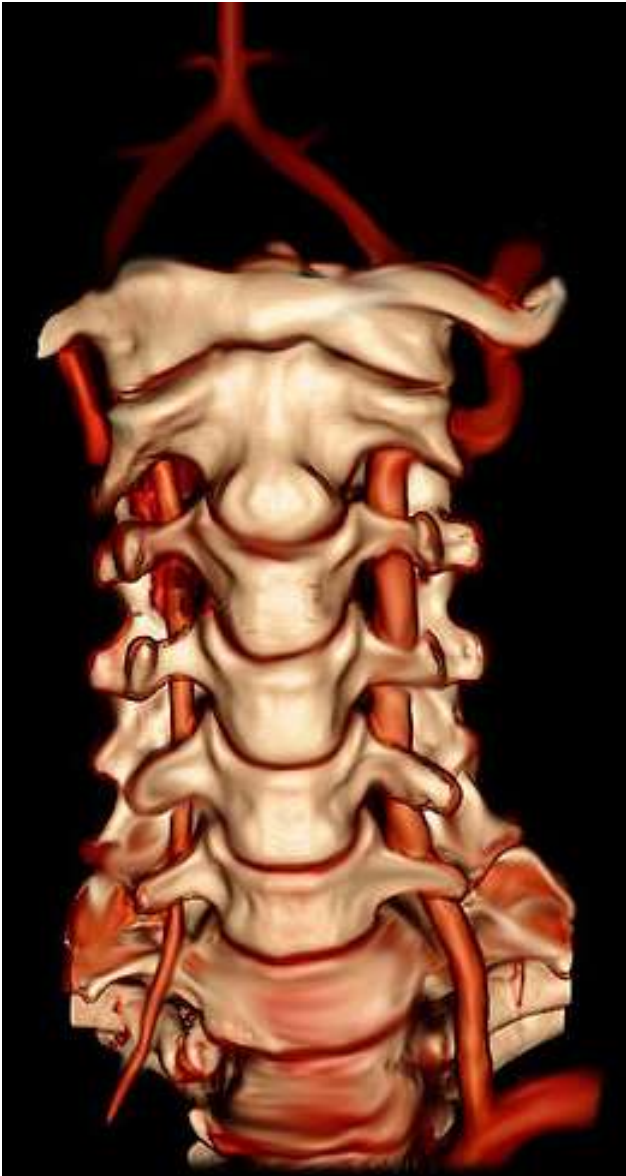Superficie ventral o anterior

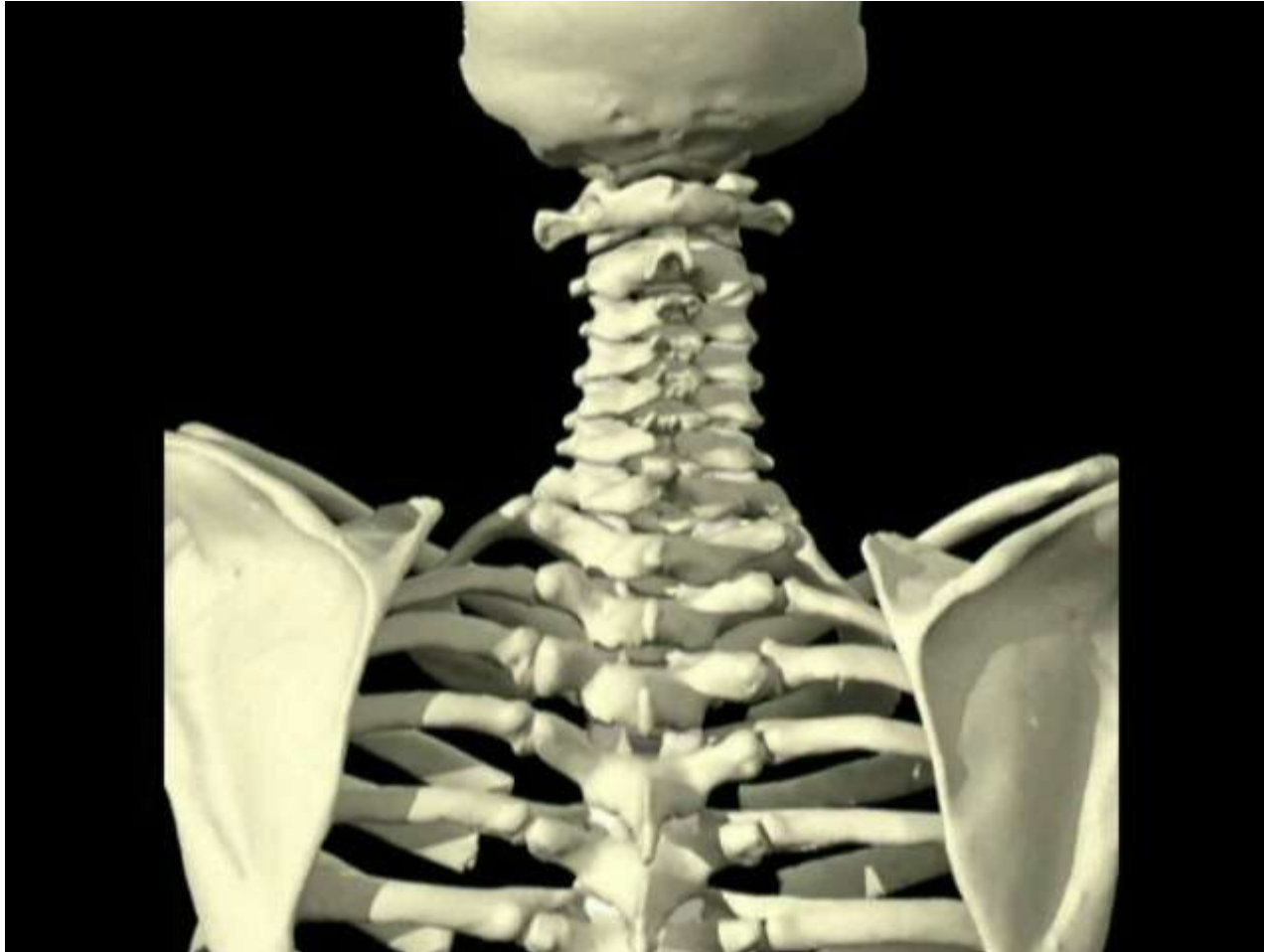(Las superficies articulares recubiertas de cartilago hialino están teñidas de azul)

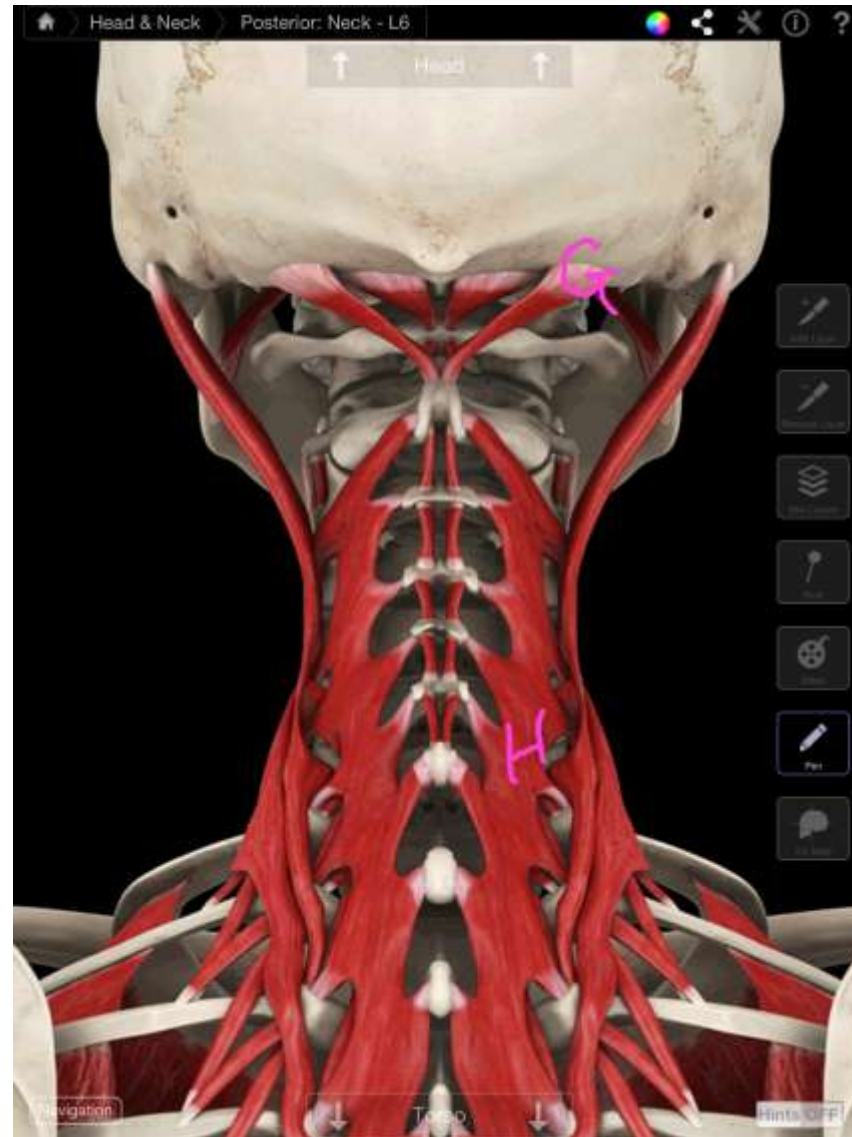






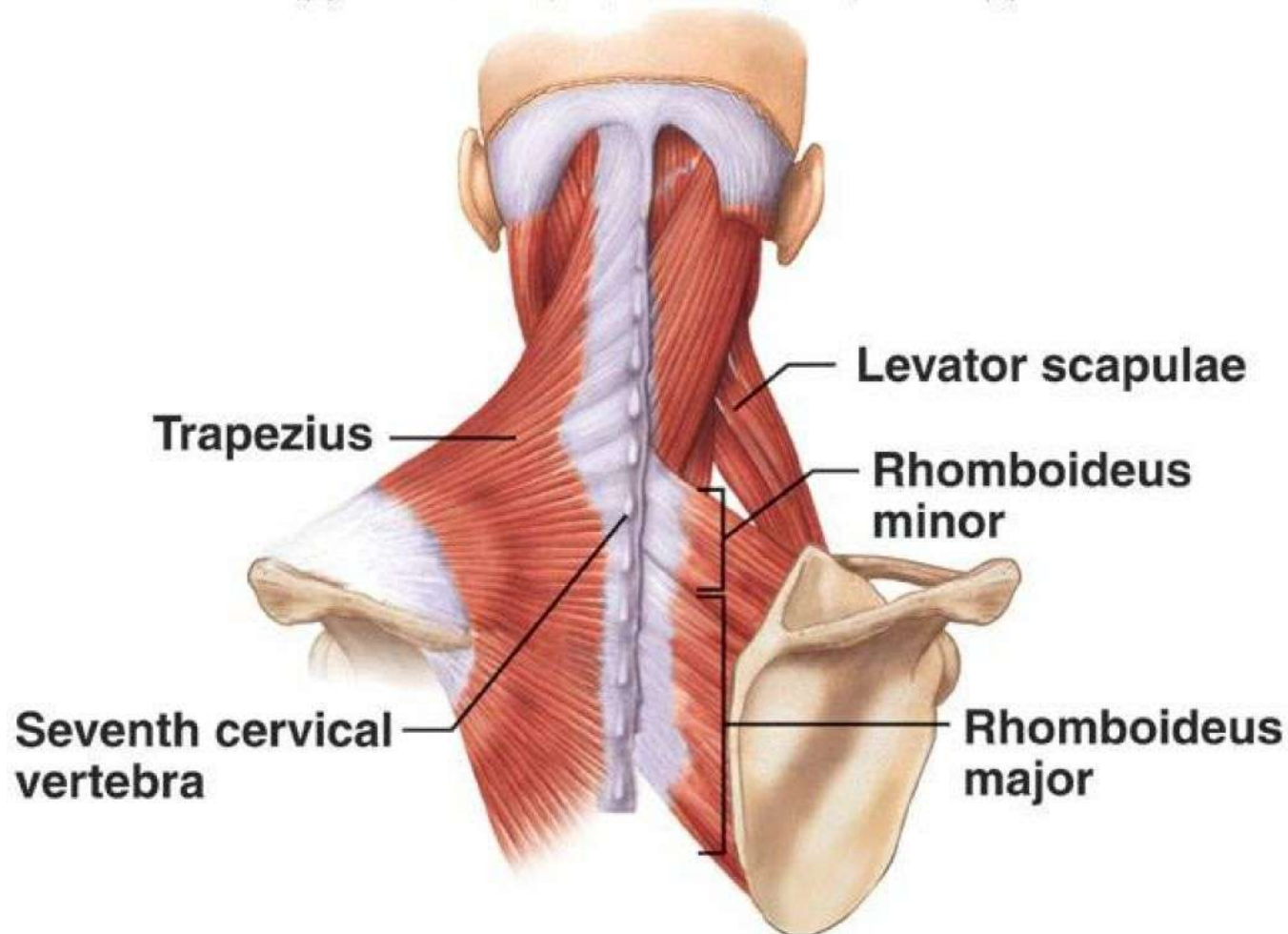


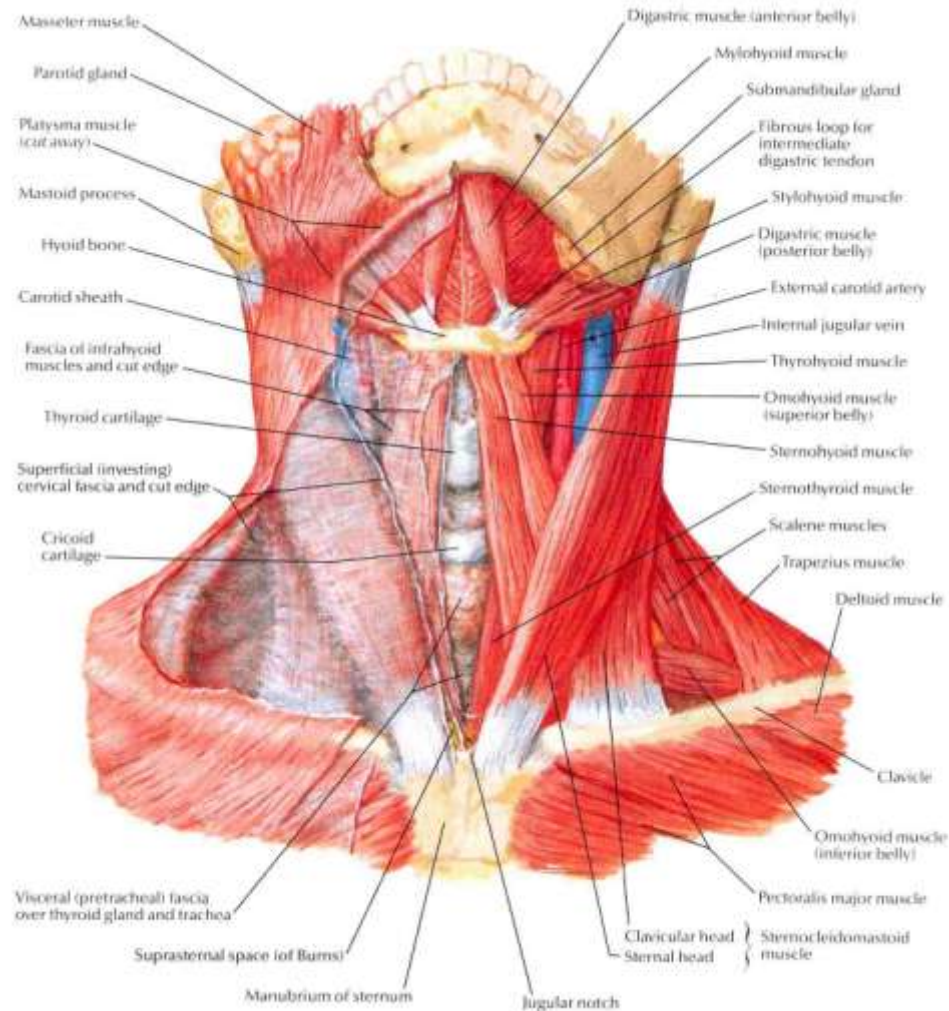




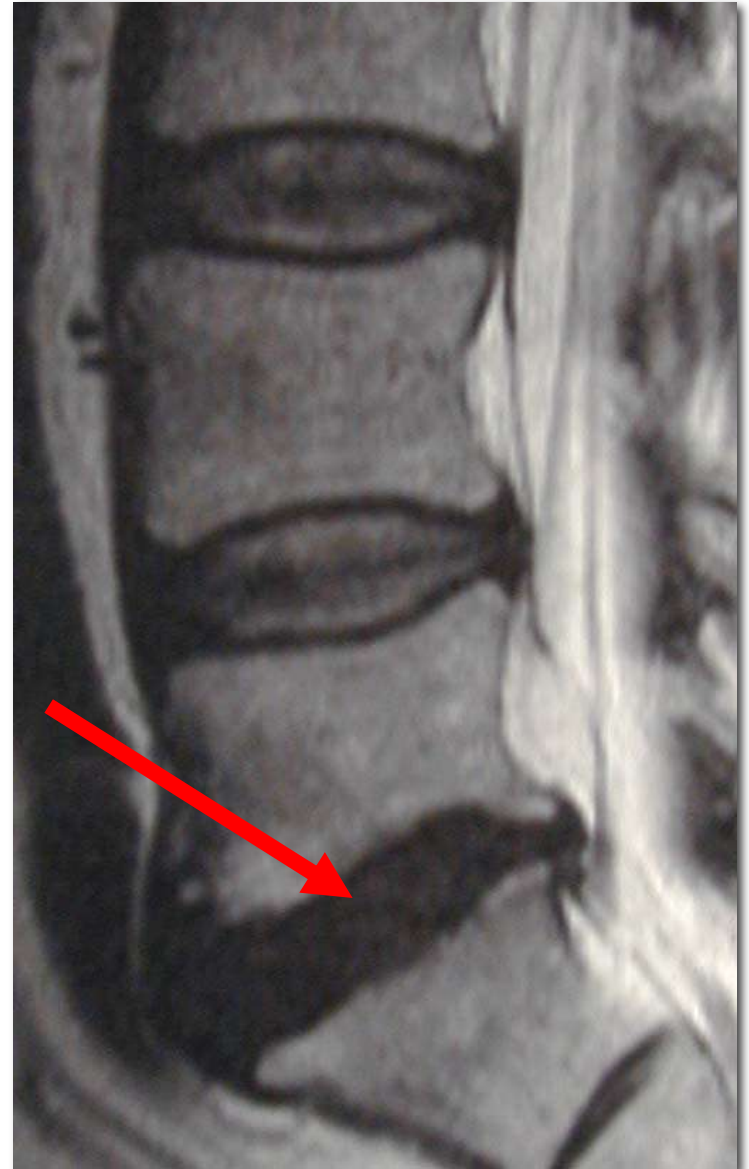
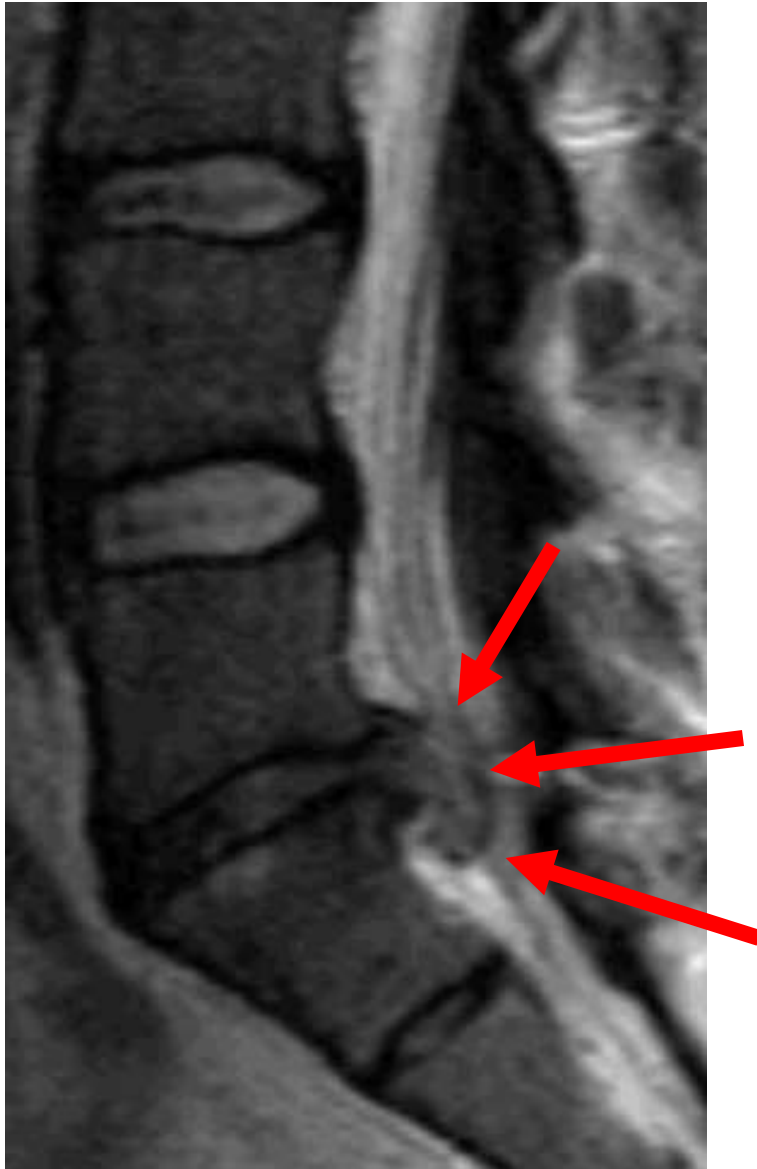

Copyright © The McGraw-Hill Companies, Inc. Permission required for reproduction or display.





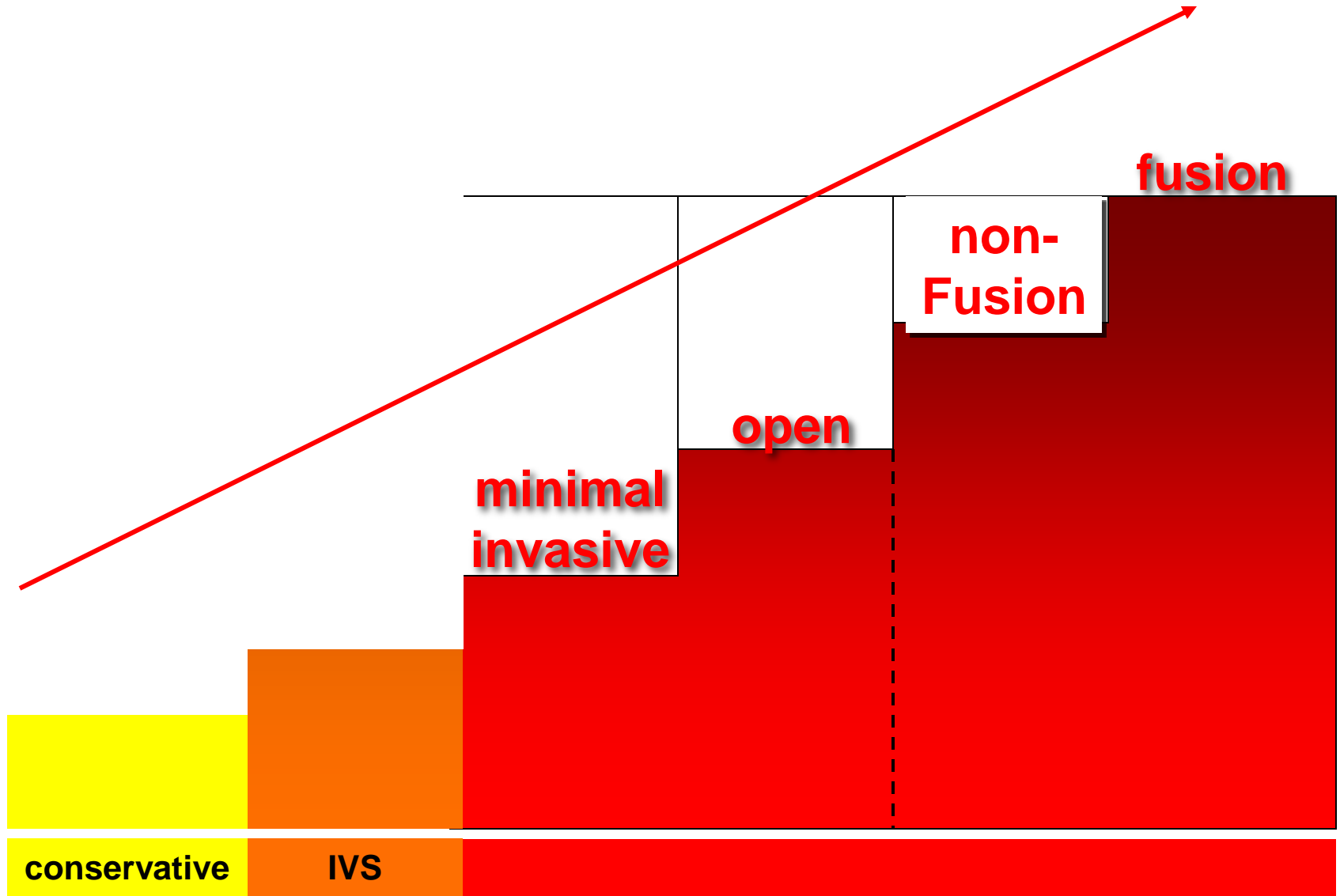
# Conservative treatment or surgery?





# Conservative treatment or surgery?

ST. ELISABETH GRUPPE  
KATHOLISCHE KLINIKEN RHEIN-RUHR



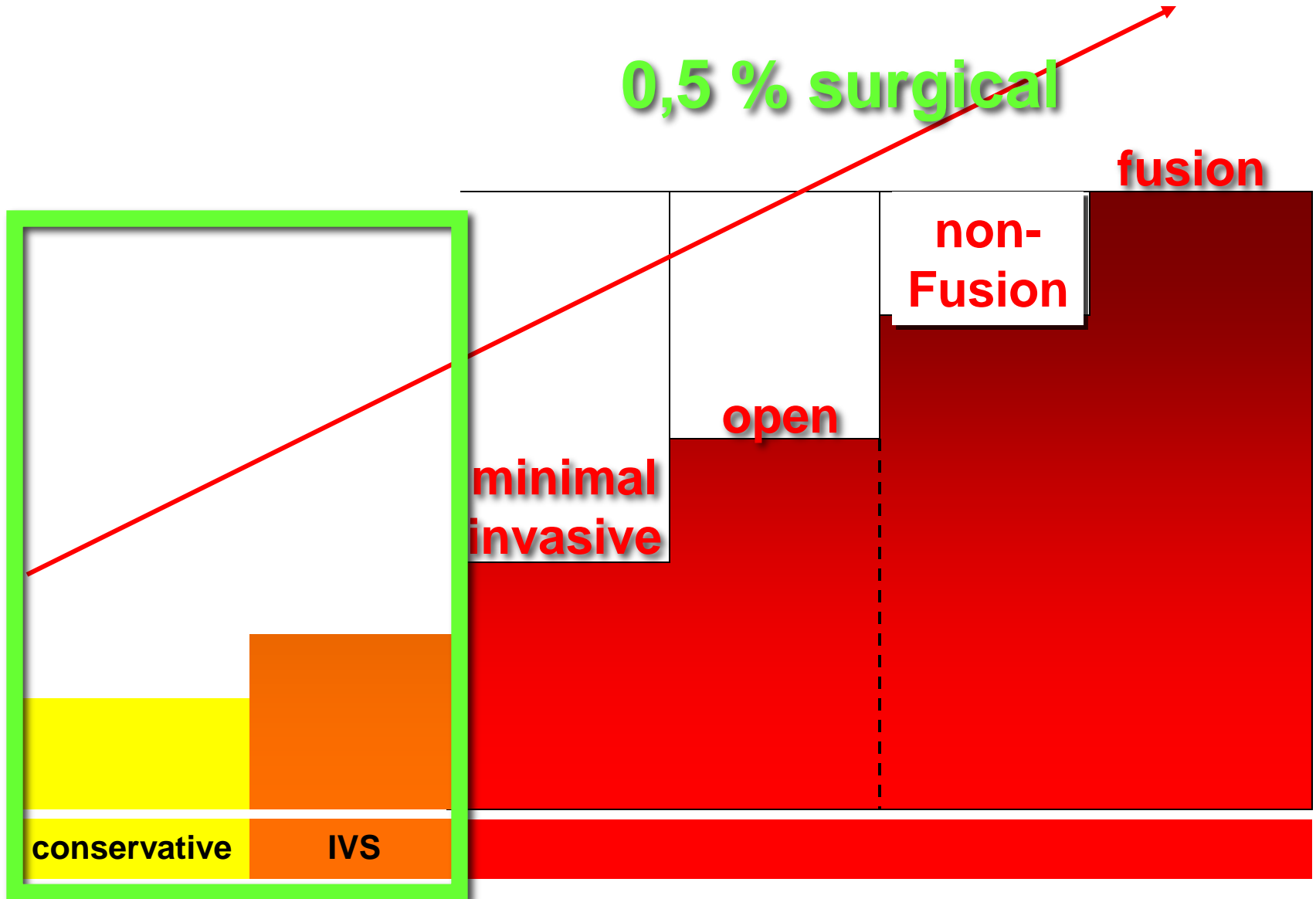


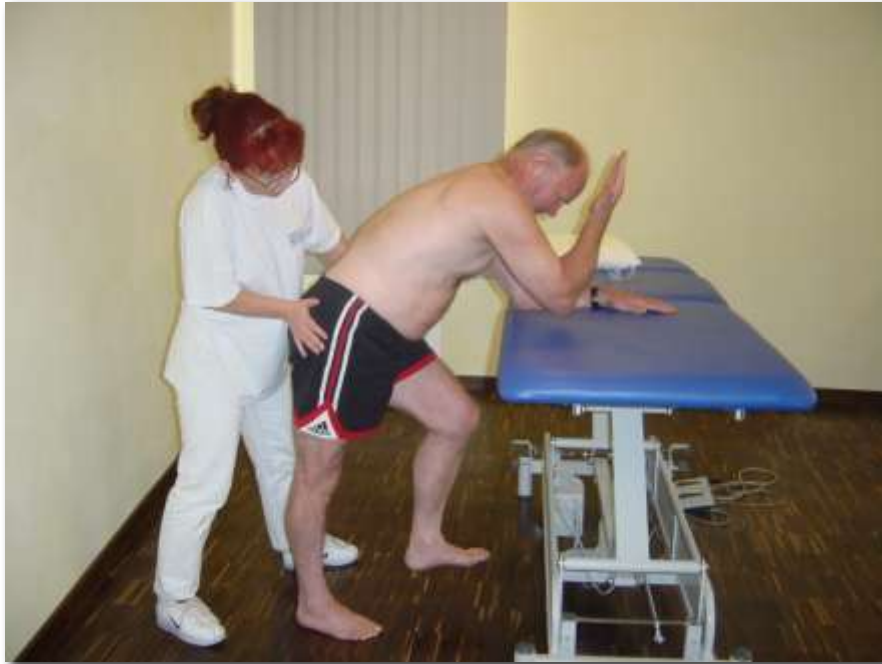

# Conservative treatment or surgery?

ST. ELISABETH GRUPPE  
KATHOLISCHE KLINIKEN RHEIN-RUHR

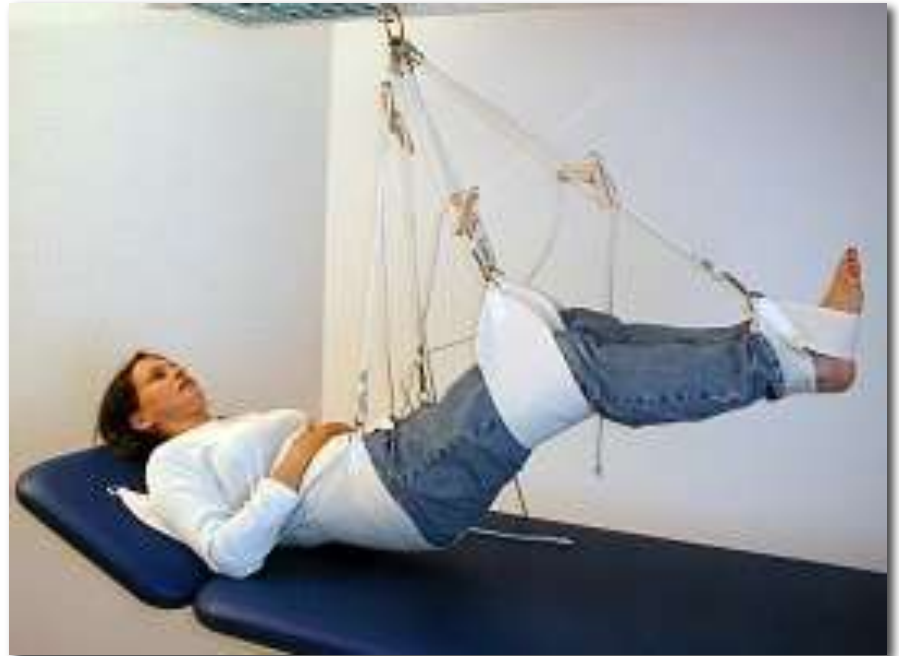0,5 % surgical





physiotherapy


## physical therapy



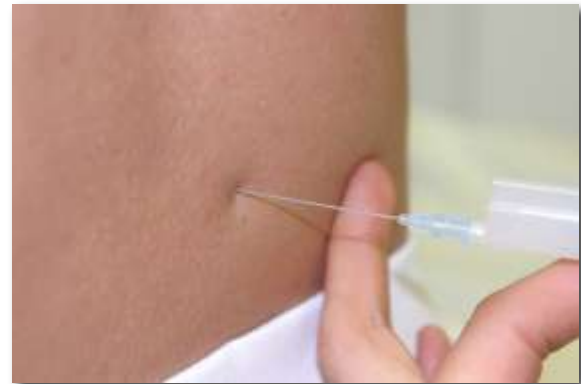## drugs



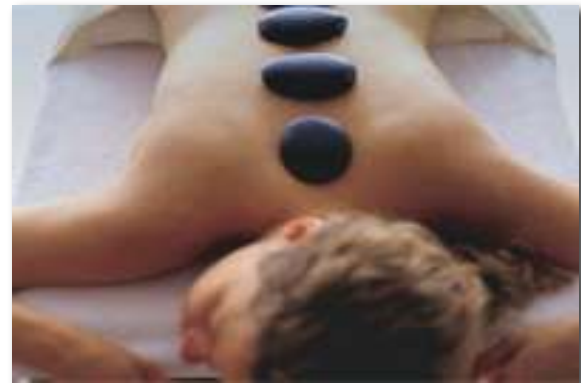## acupuncture



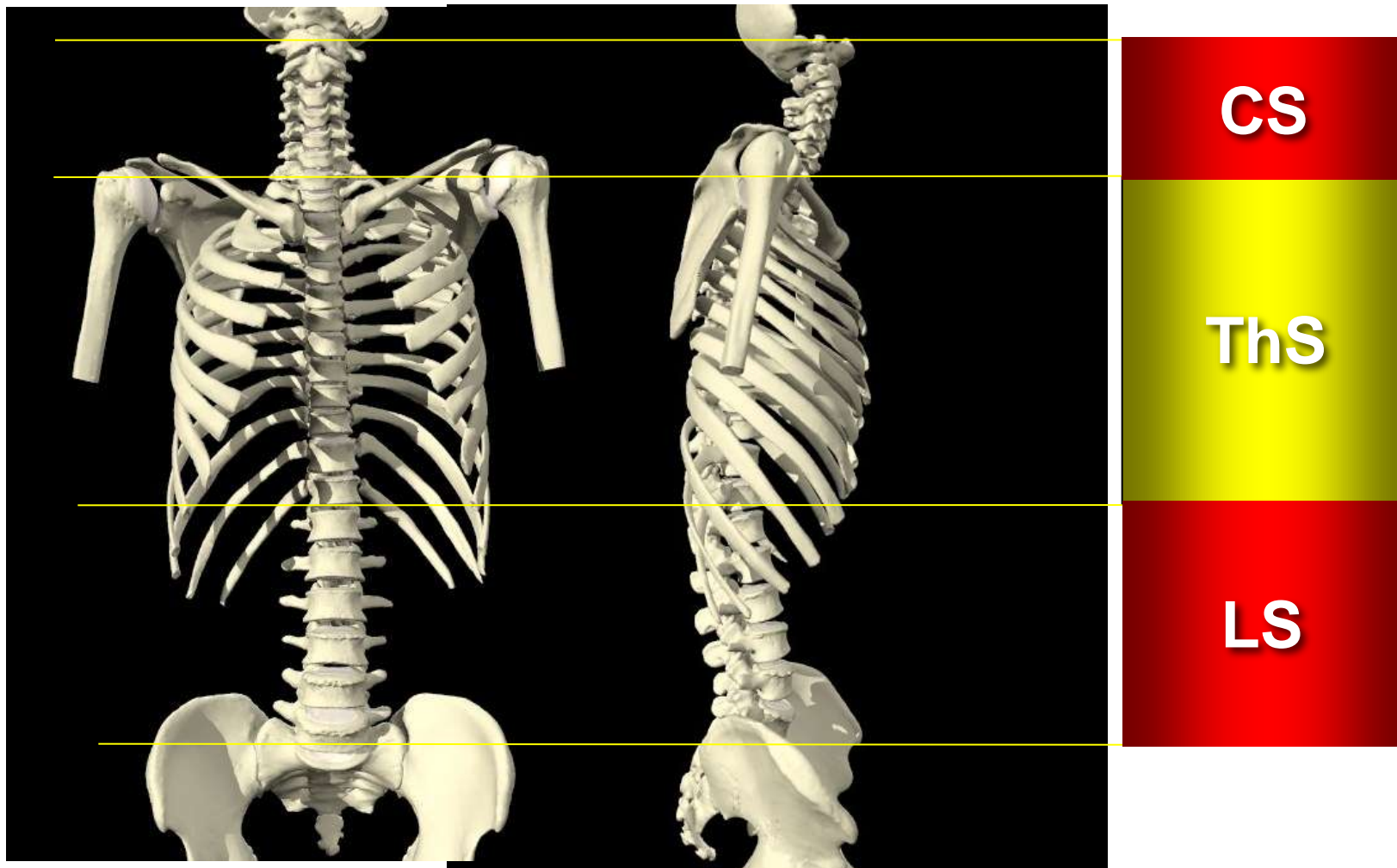
## injections



## others



# C-Arm Injections

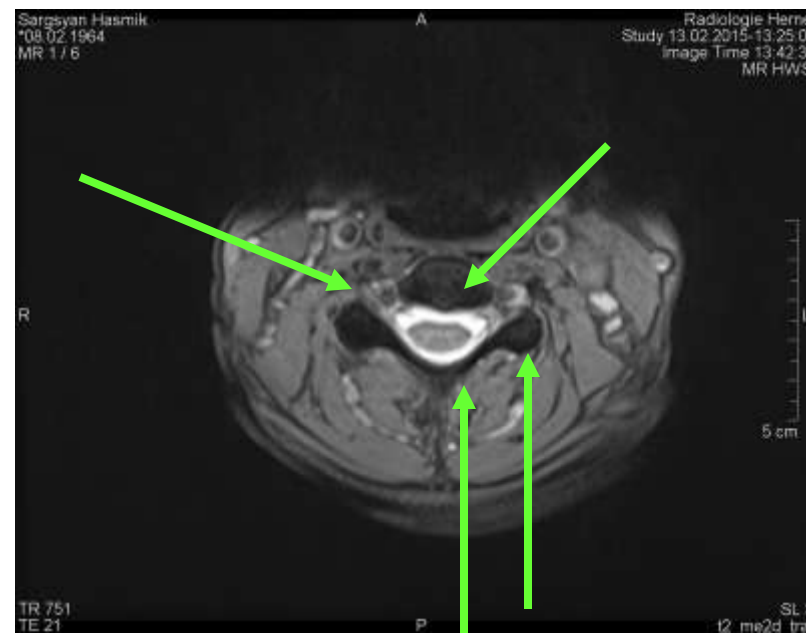
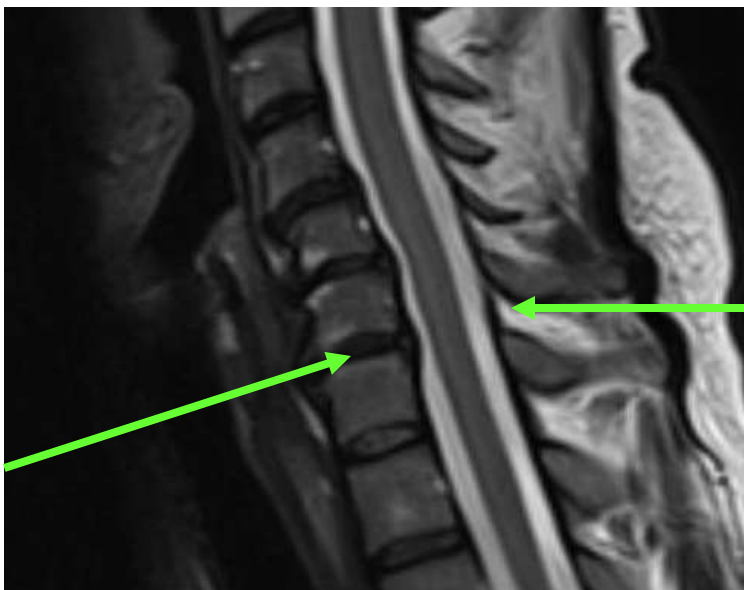


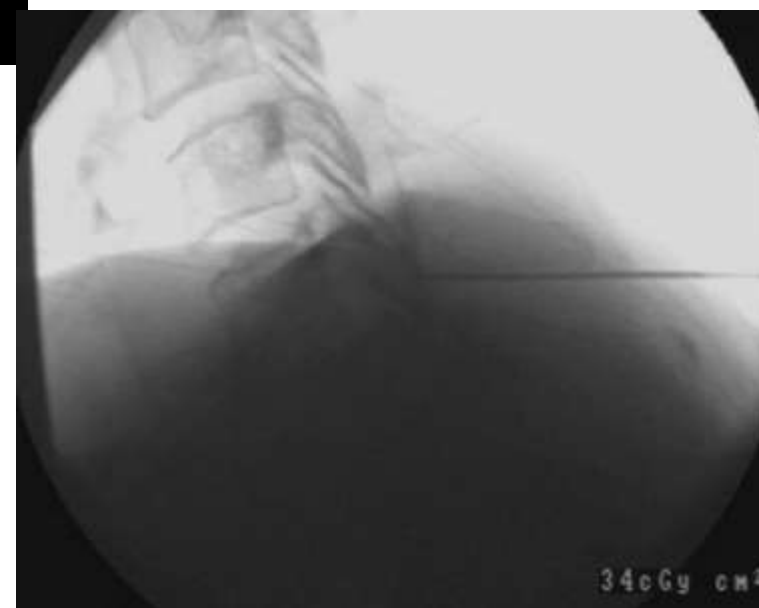
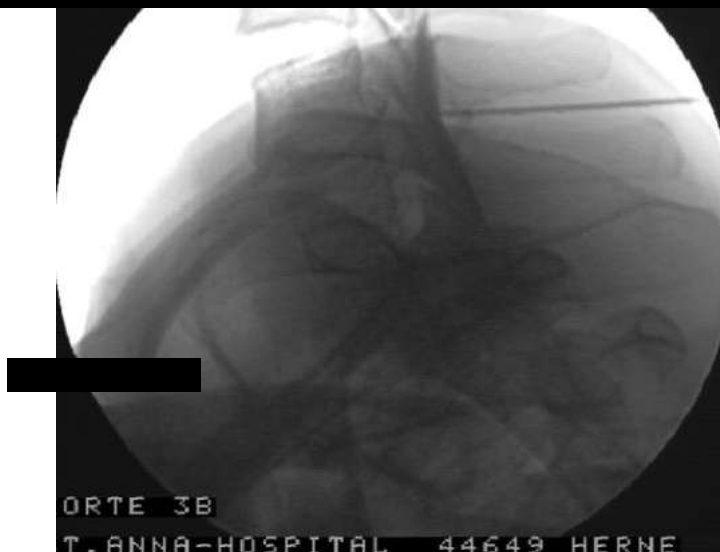
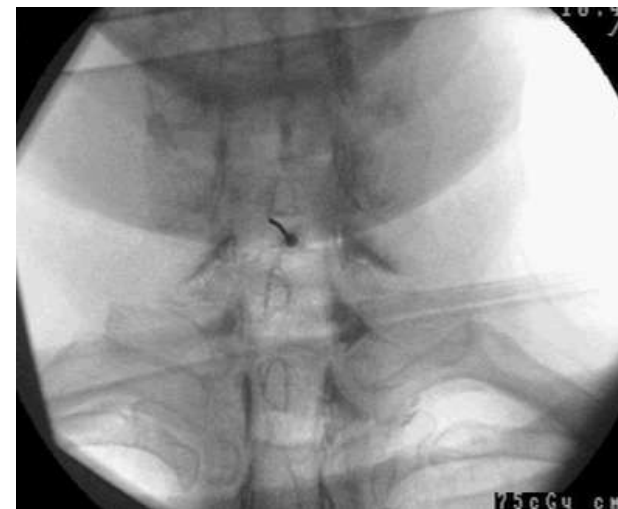
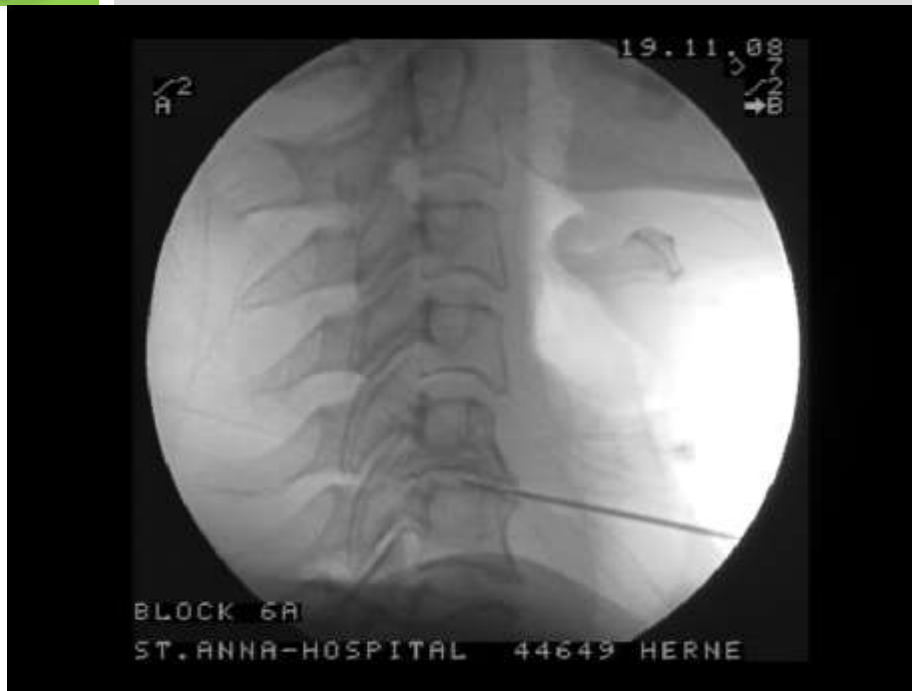dorsal

transforaminal

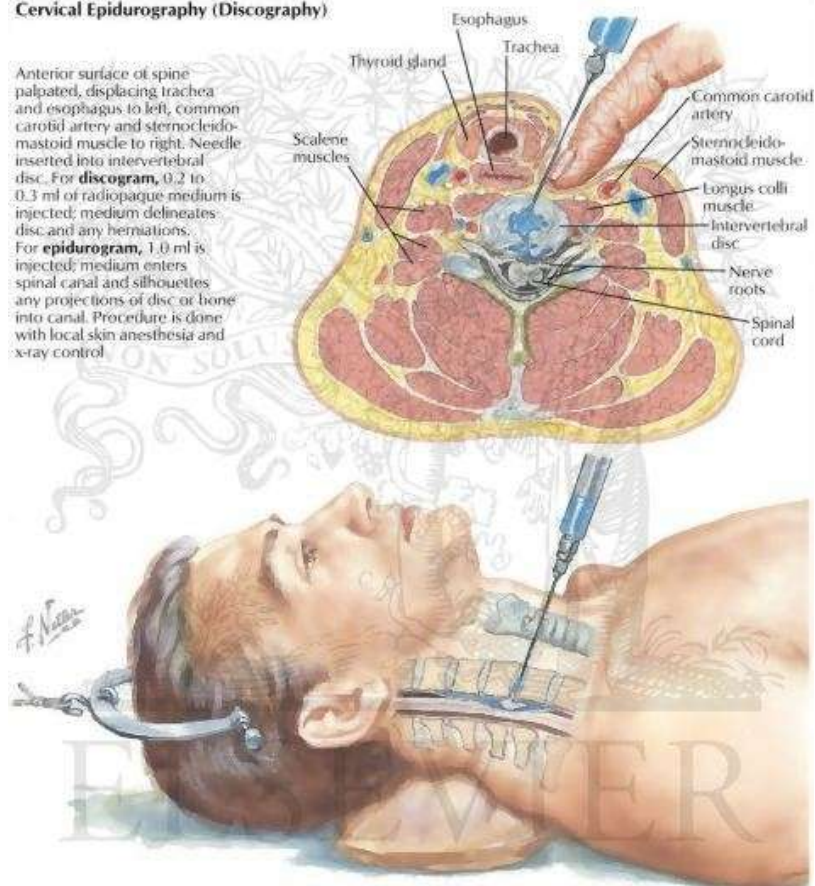
intradiscal





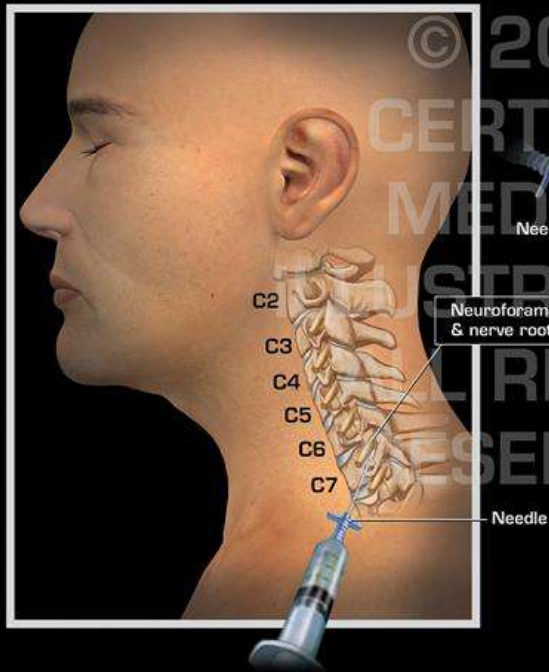
### Cervical Epidurography (Discography)

Anterior surface of spine palpated, displacing trachea and esophagus to left, common carotid artery and sternocleidomastoid muscle to right. Needle inserted into intervertebral disc. For **discogram**, 0.2 to 0.3 ml of radiopaque medium is injected; medium delineates disc and any herniations. For **epidurogram**, 1.0 ml is injected; medium enters spinal canal and silhouettes any projections of disc or bone into canal. Procedure is done with local skin anesthesia and x-ray control.

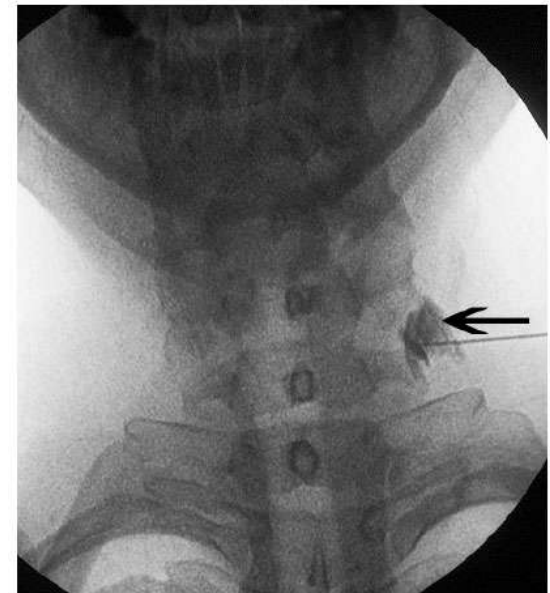
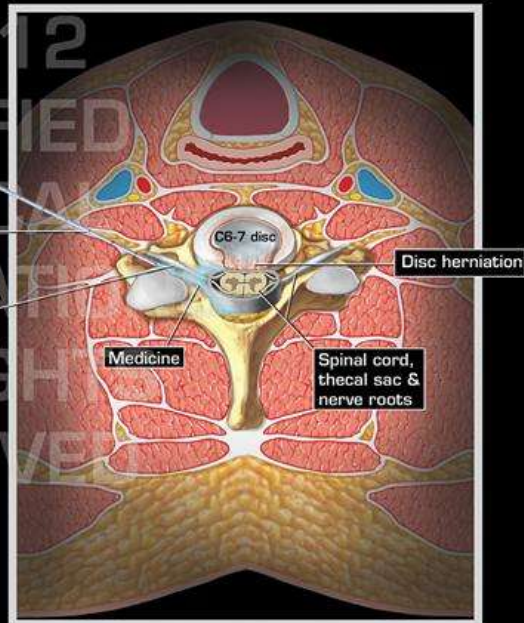


## TRANSFORAMINAL EPIDURAL STEROID INJECTION OF CERVICAL SPINE

A. Placement of Needle into Left ( Right )  
Neuroforamen at C6-7

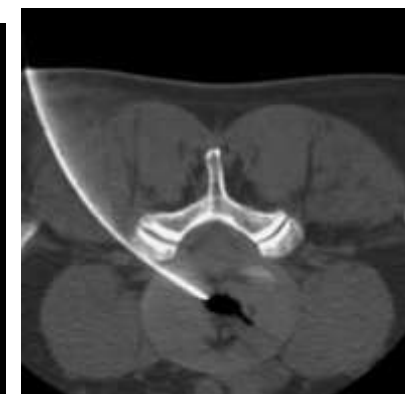
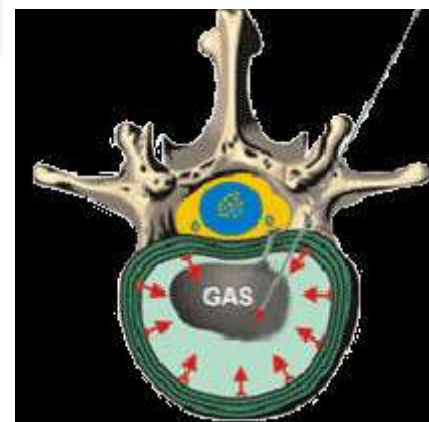
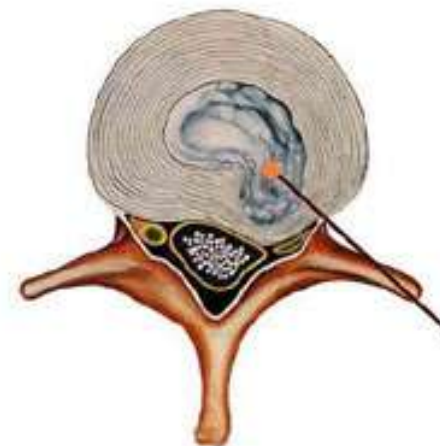
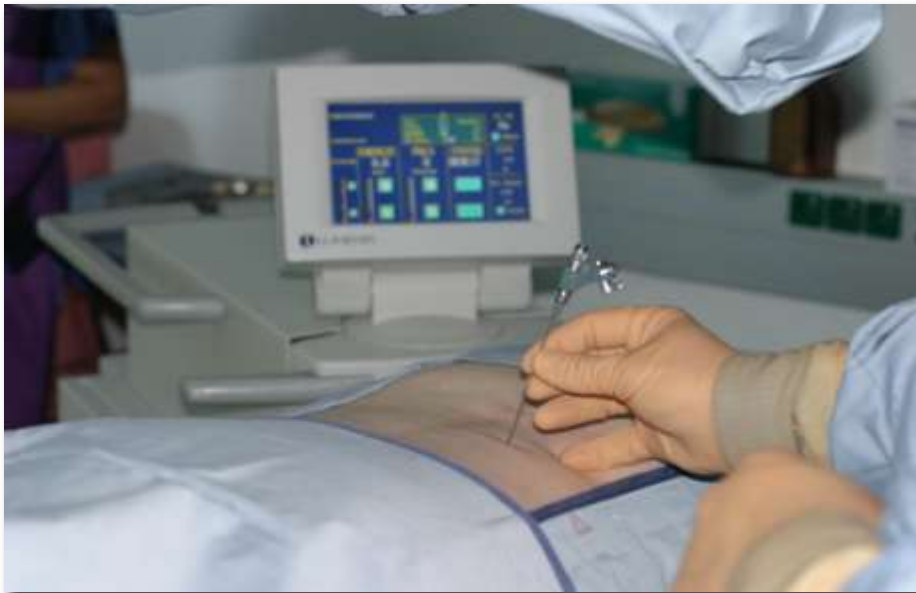B. Epidurogram & Injection of Steroid into  
Epidural Space at Left ( Right ) C6-7,  
Axial Section



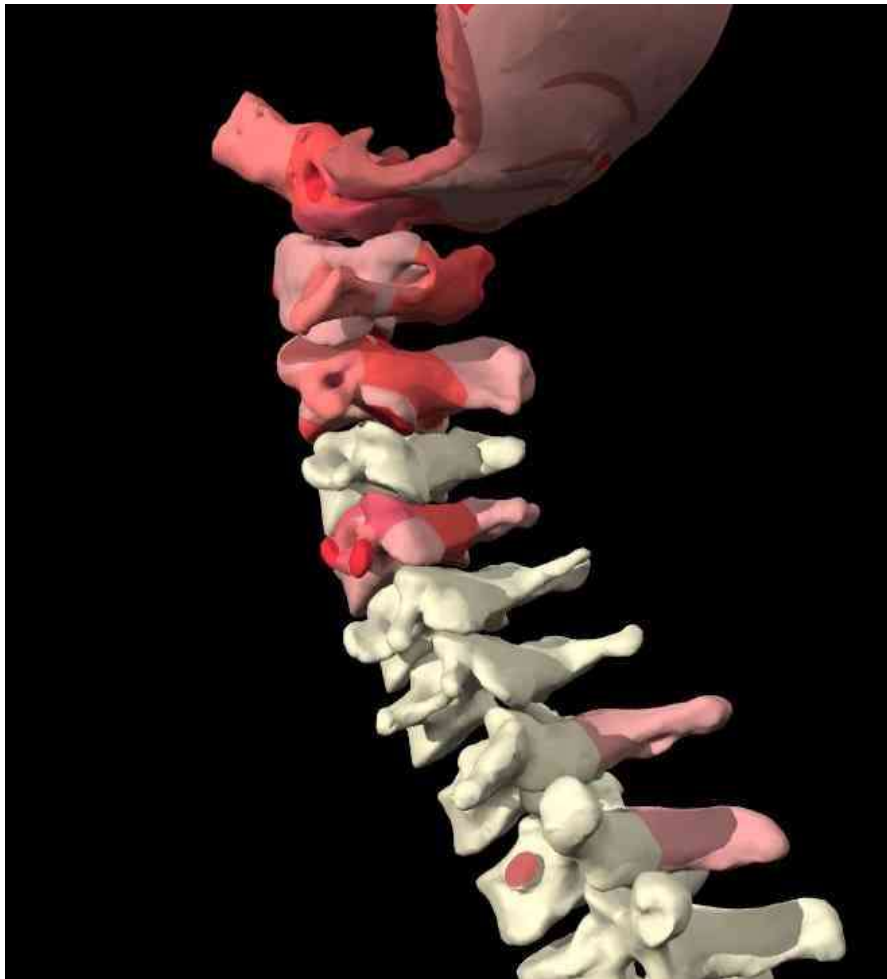


## percutane laser disc decompression

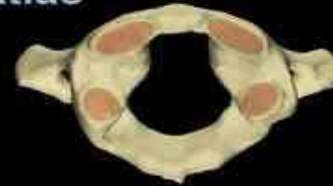



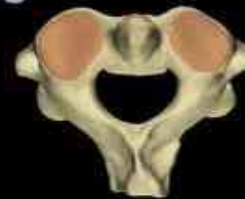# **Surgical treatment of degenerative diseases and injuries of the cervical spine**



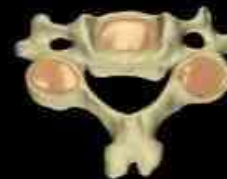Atlas



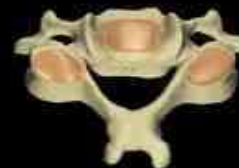Axis



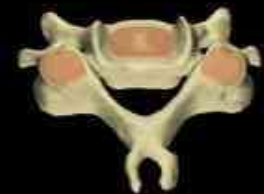C3



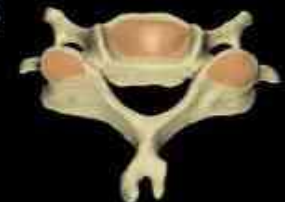C4



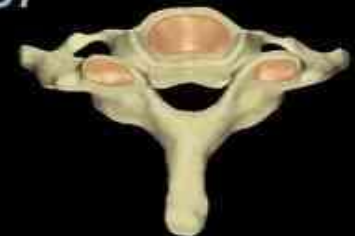C5



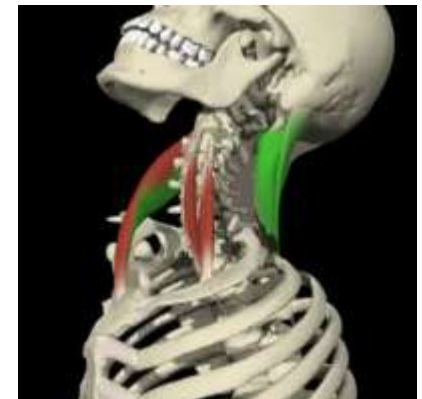
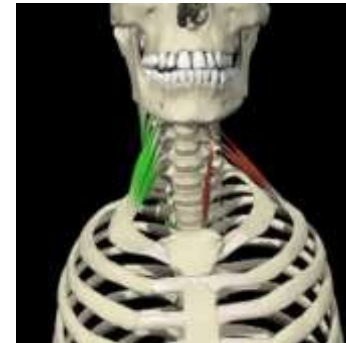
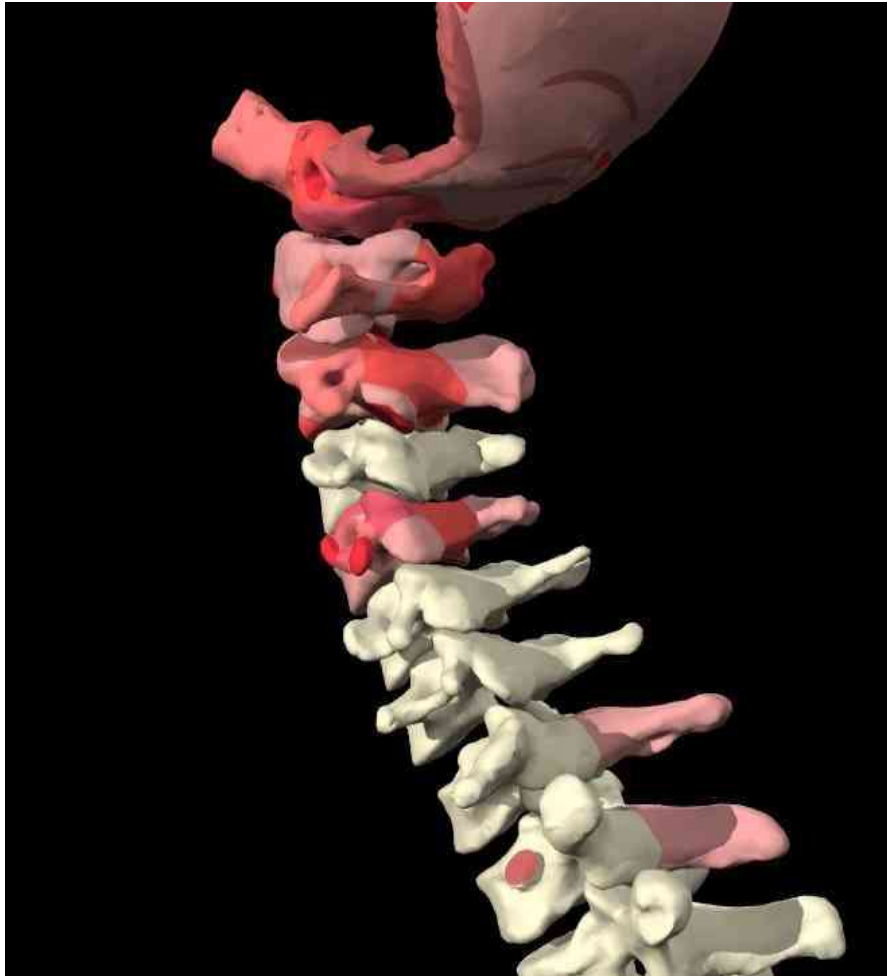
C6

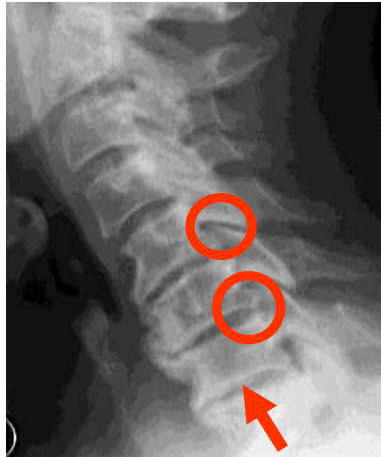

C7



# ventral endoscopic nucleotomy

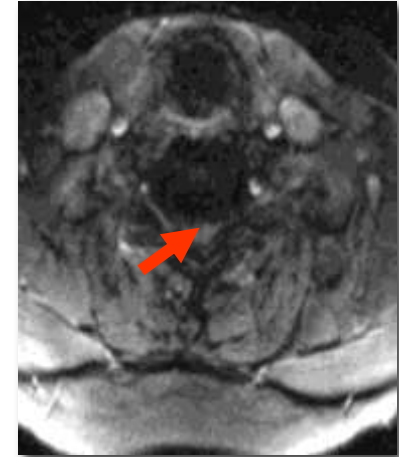




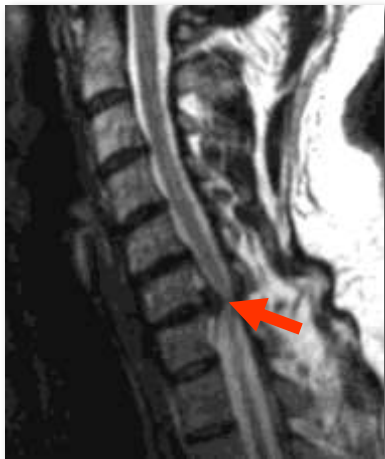**Discusdegeneration**

**Osteophytes**

**Facette-Arthrosis**



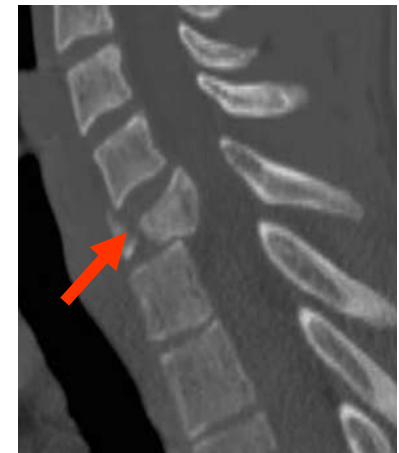**SCS**



**Herniations**

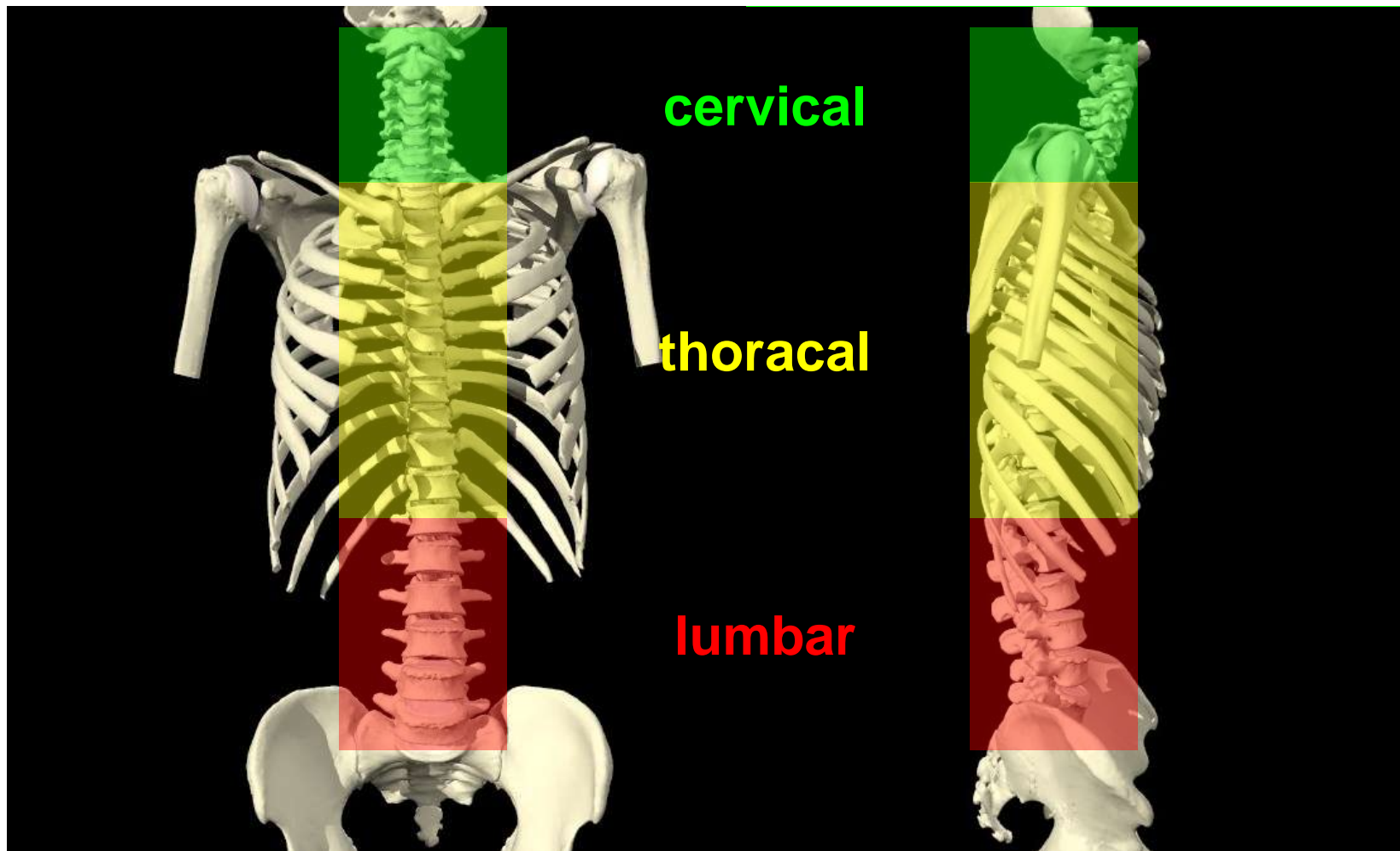
**Fracture**

**Inflammatory disease**



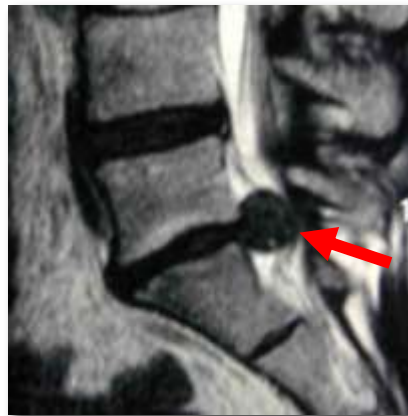
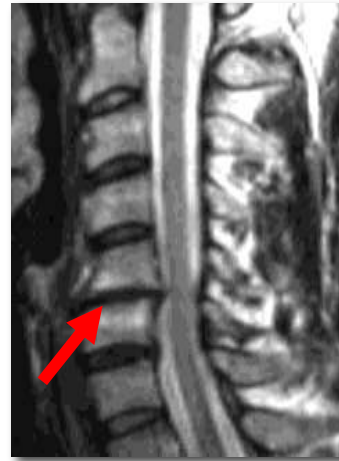
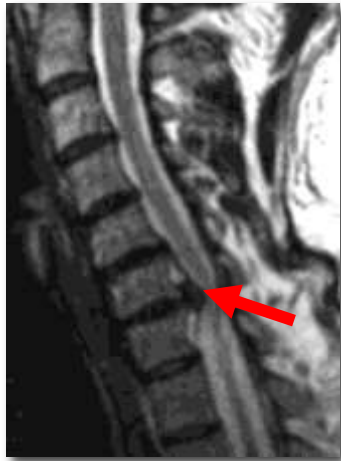

# Fullendoscopic operations

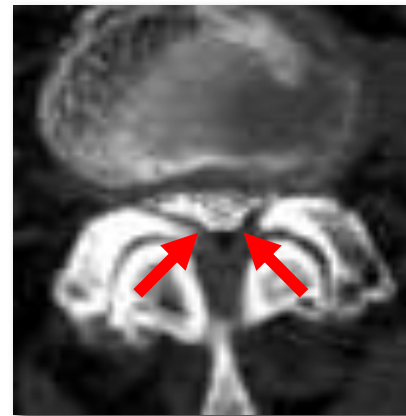


# Fullendoscopic operations





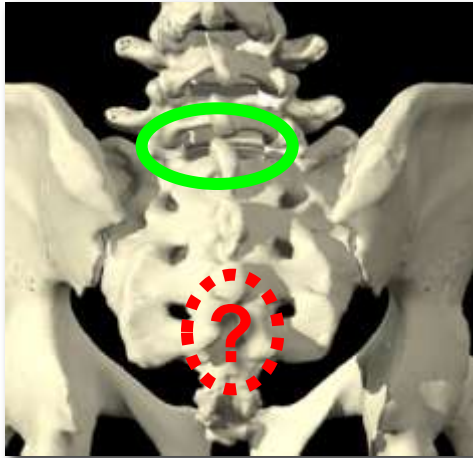
NPP



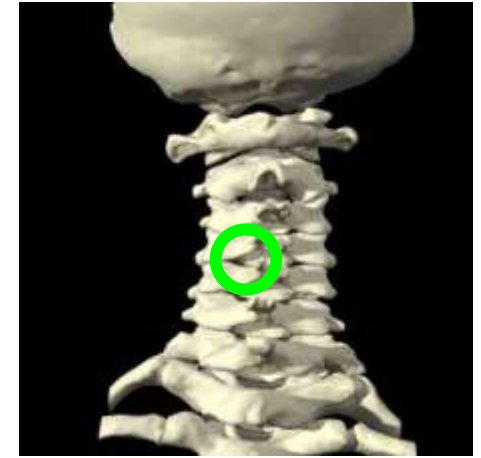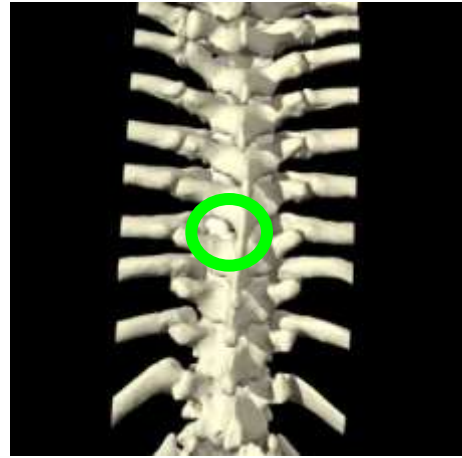
SCS

## Radicular Symtoms

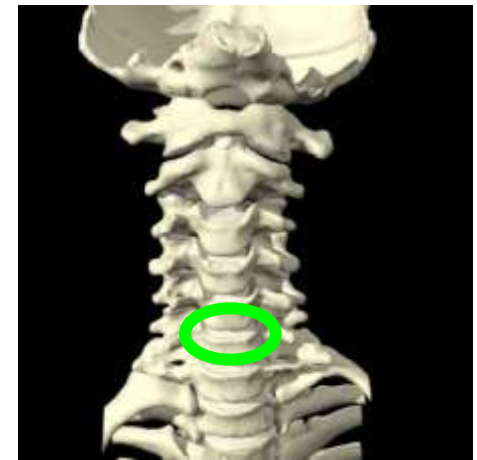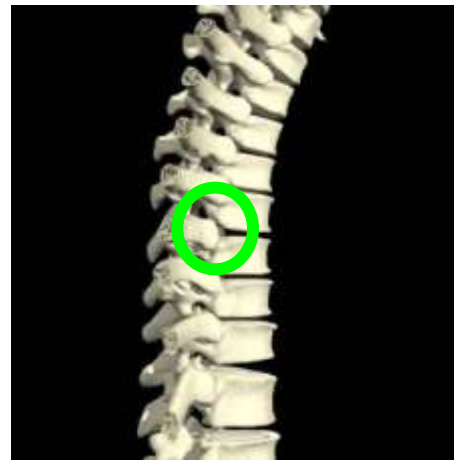
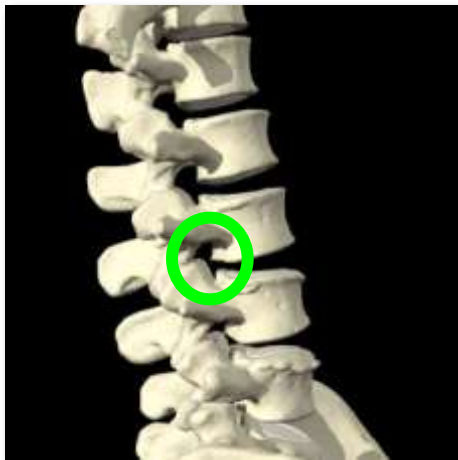# Fullendoscopic operations



interlaminär



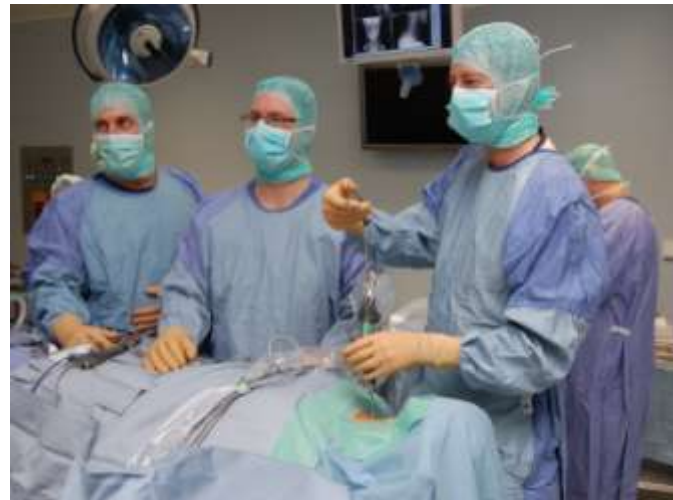
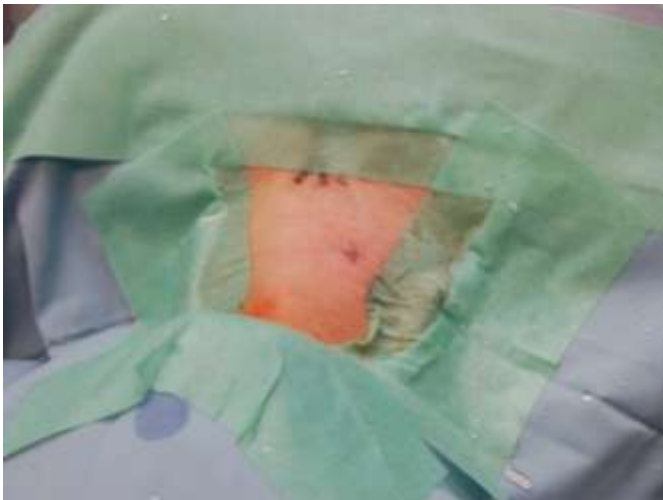
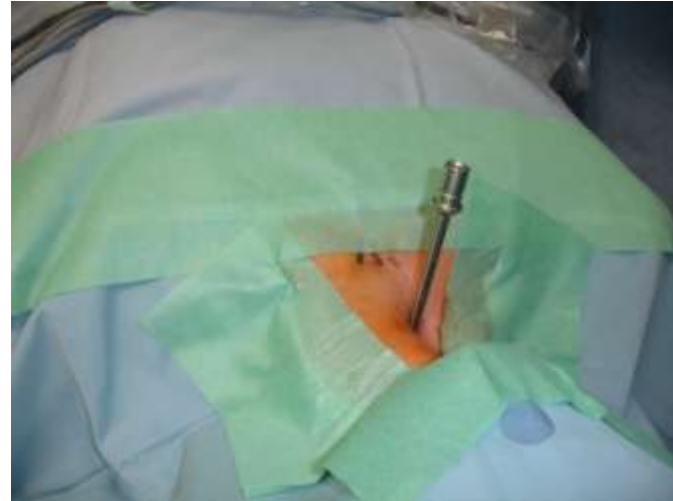
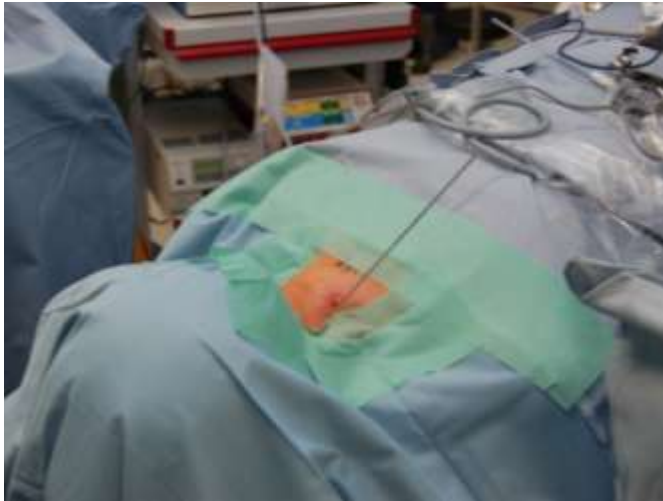
dorsal



ventral

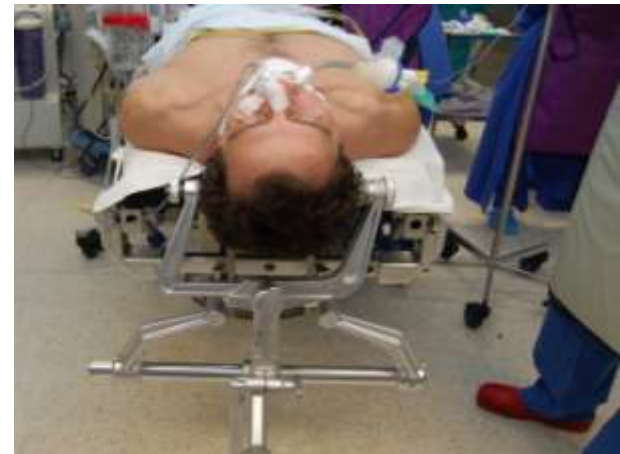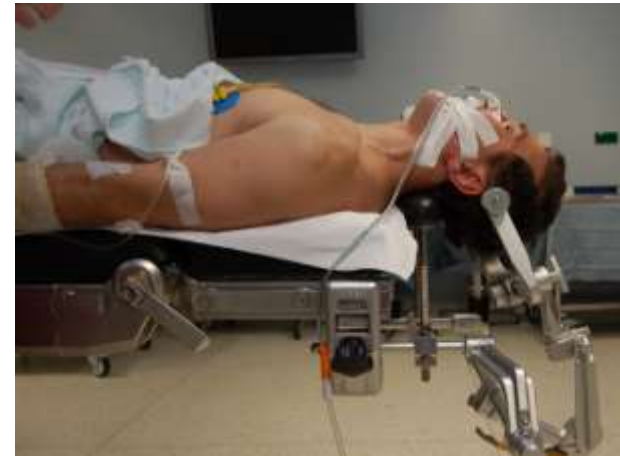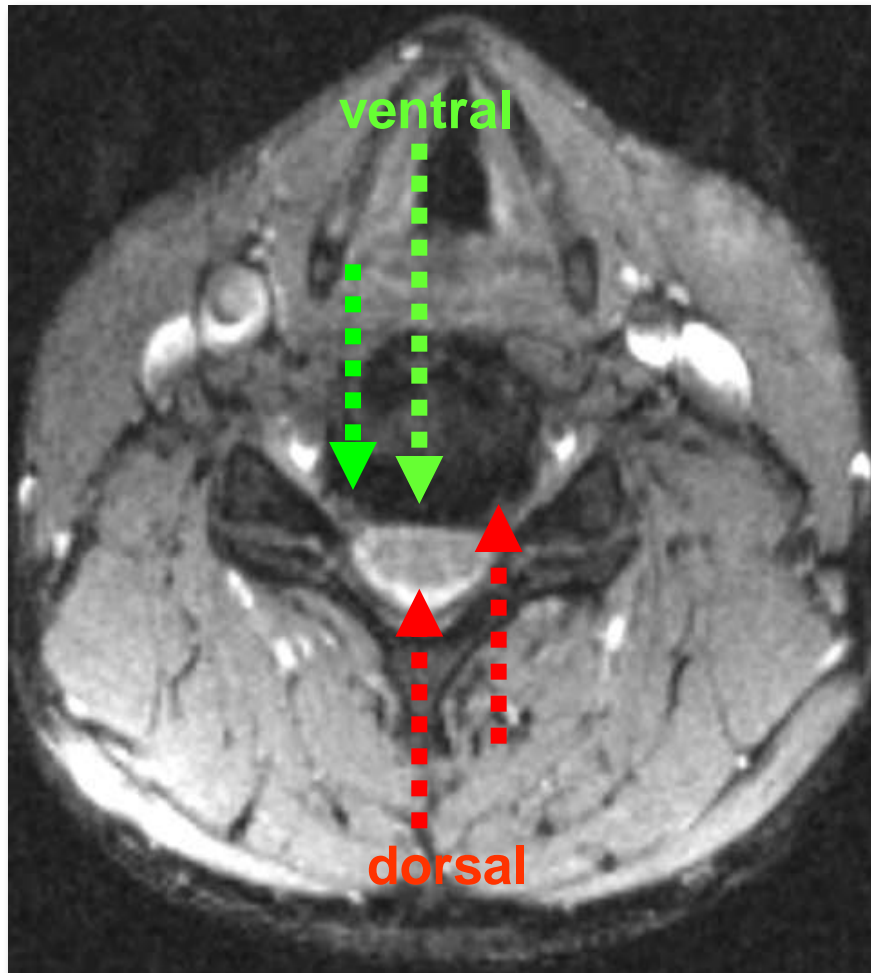


# Fullendoscopic operations



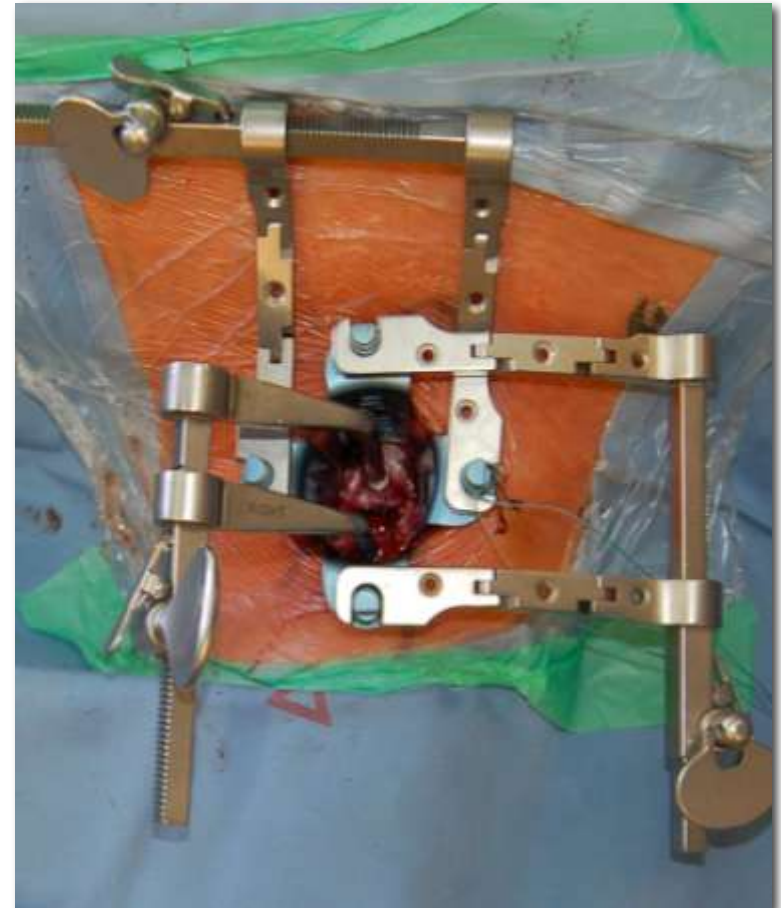
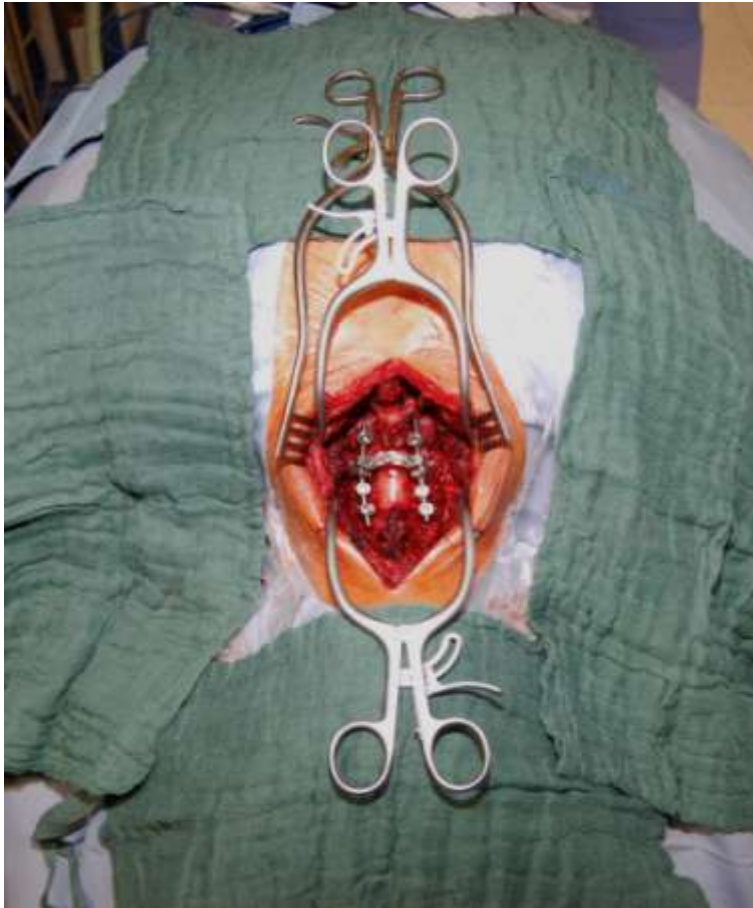


# Open operation techniques



# Open operation techniques

## open operation dorsal/ventral

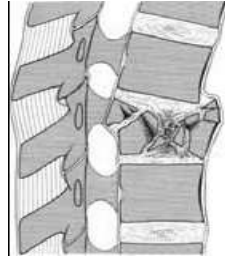
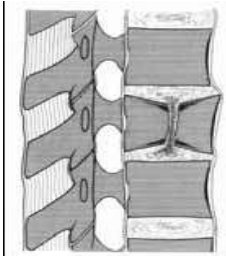
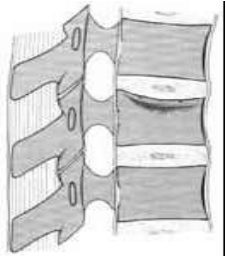


# Fractures

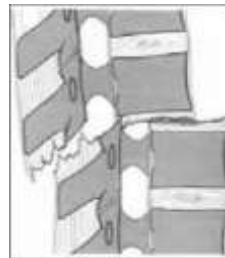
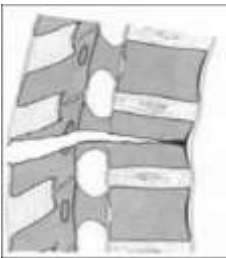
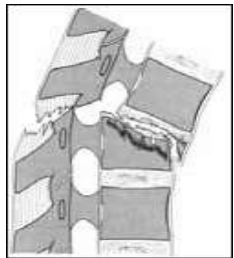


- car accidents
- young men
- high rate of collateral fractures

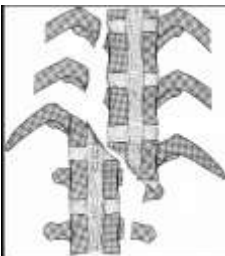
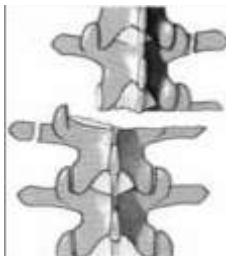
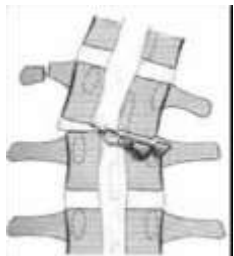
# Fractures



Typ A : Compression fractures



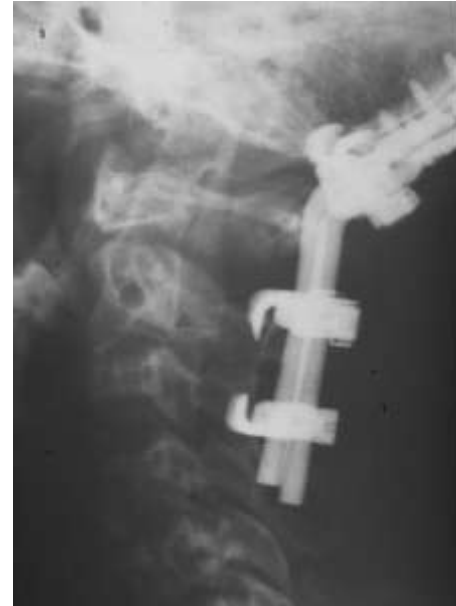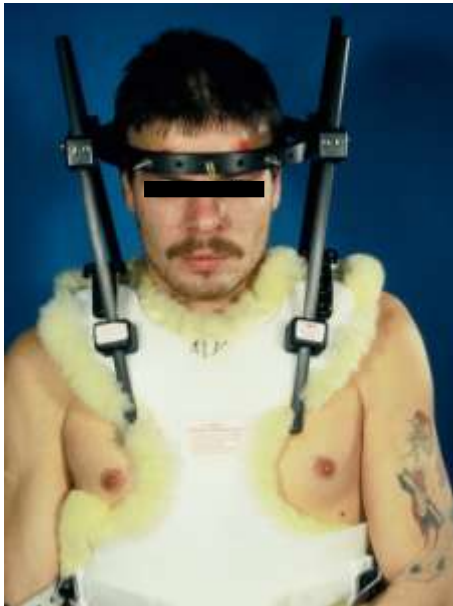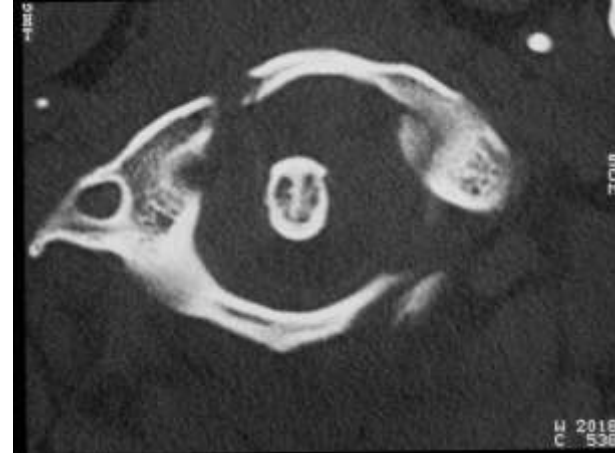
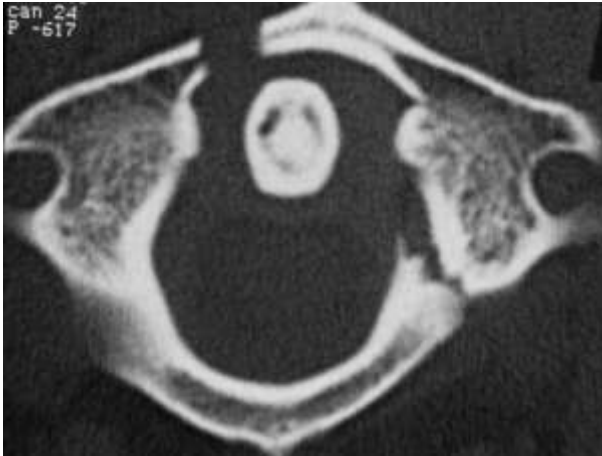Typ B : Distraction fractures



Typ C : Rotation fracture

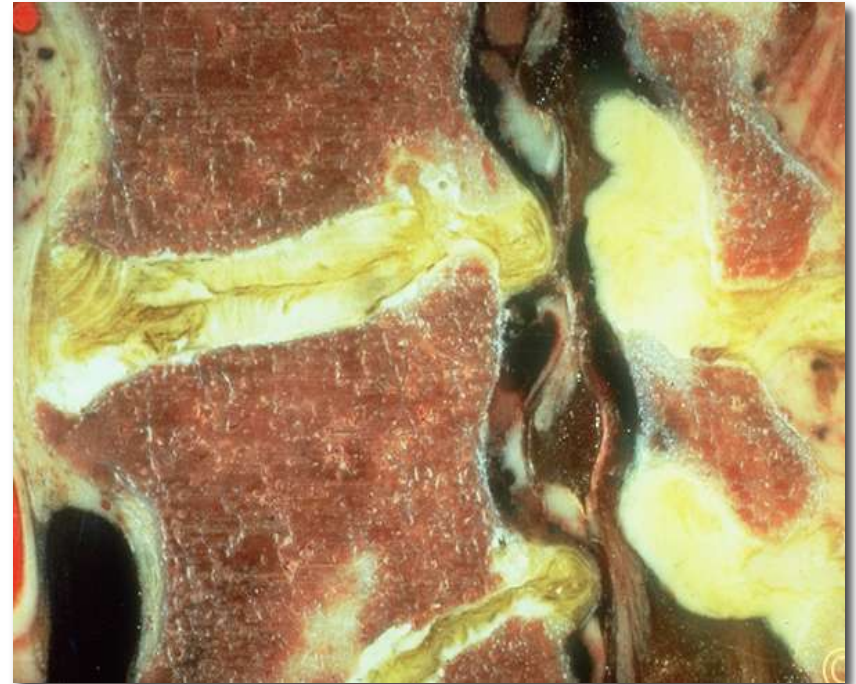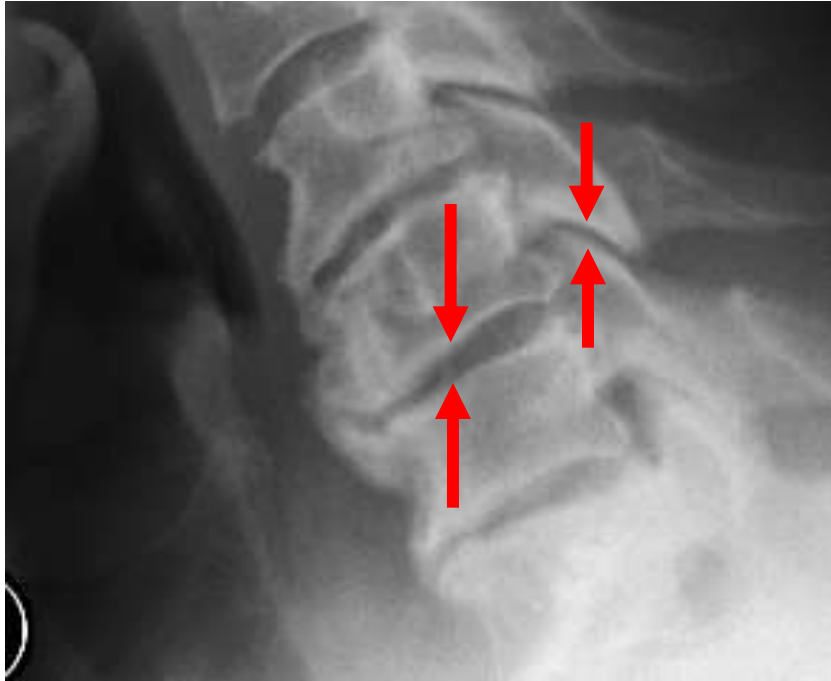


## Atlas fractures



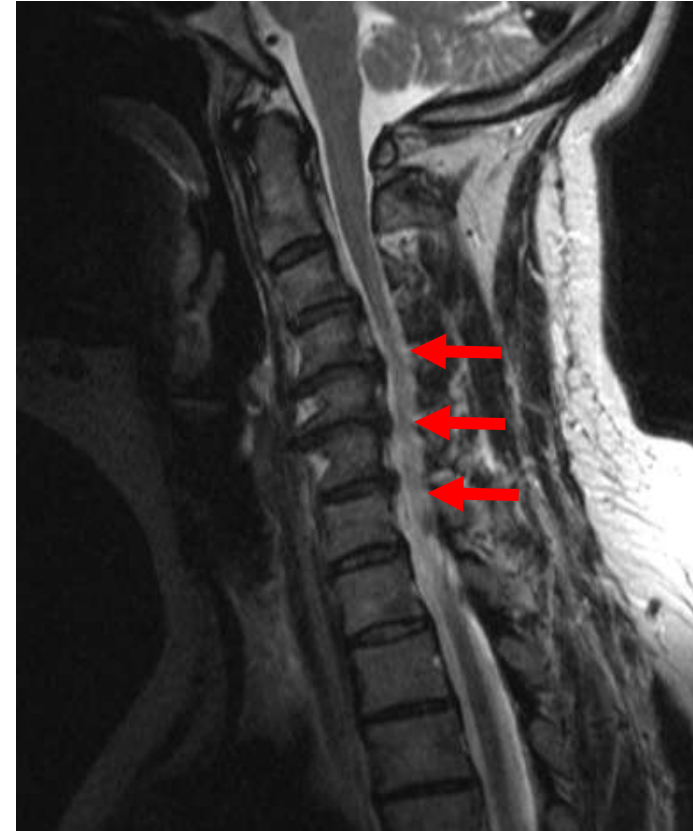
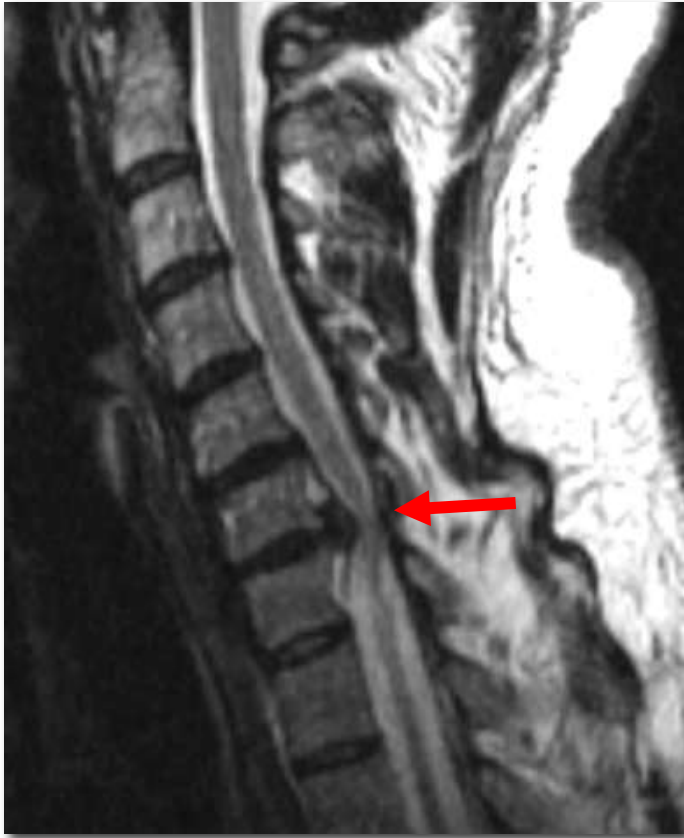
# Degenerative disease



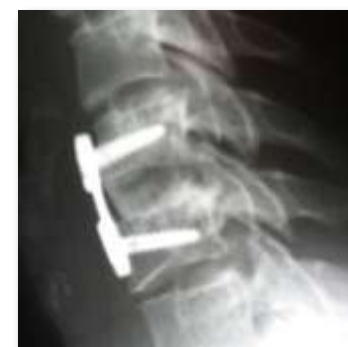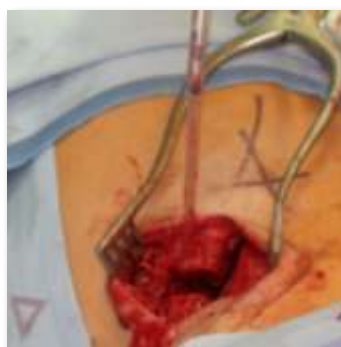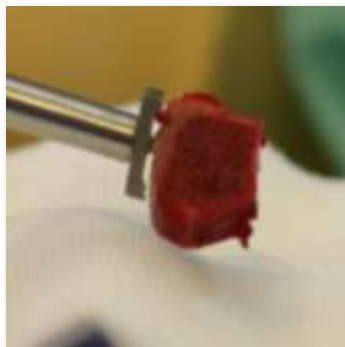


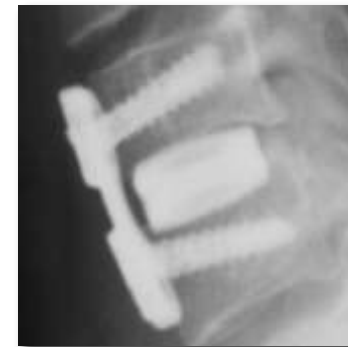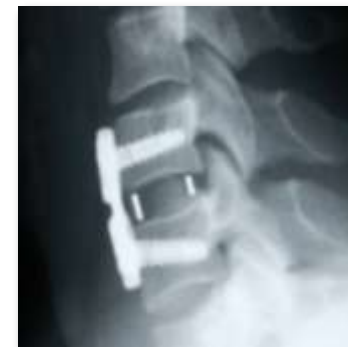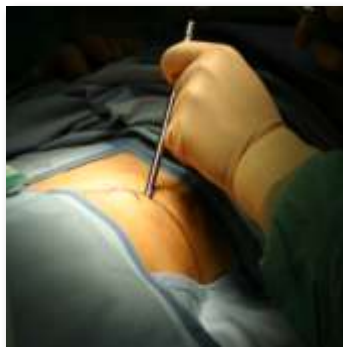- disc height reduction
- facet degeneration
- foraminal stenosis

# Degenerative disease

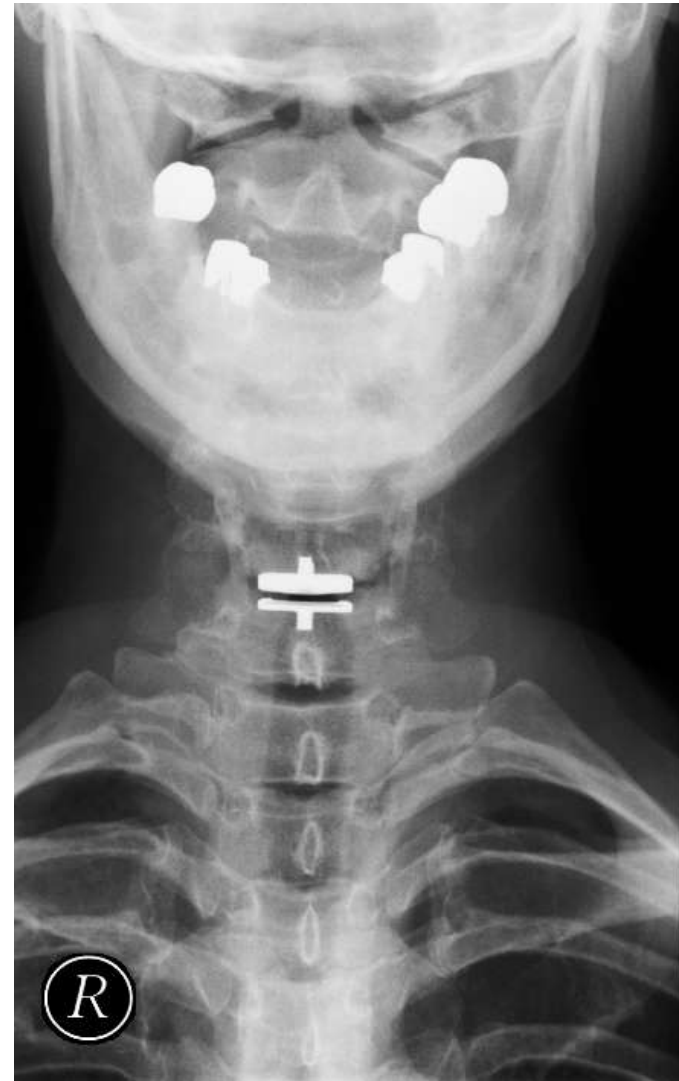
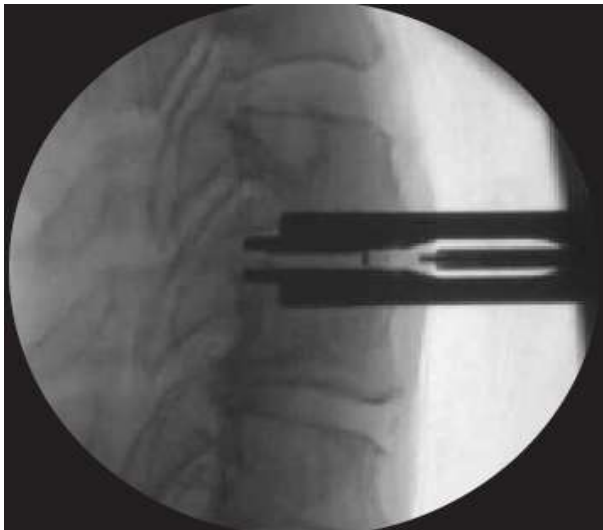
**NPP, spinal canal stenosis, myelon compression  
pain, dysaesthesia, lost of strength**

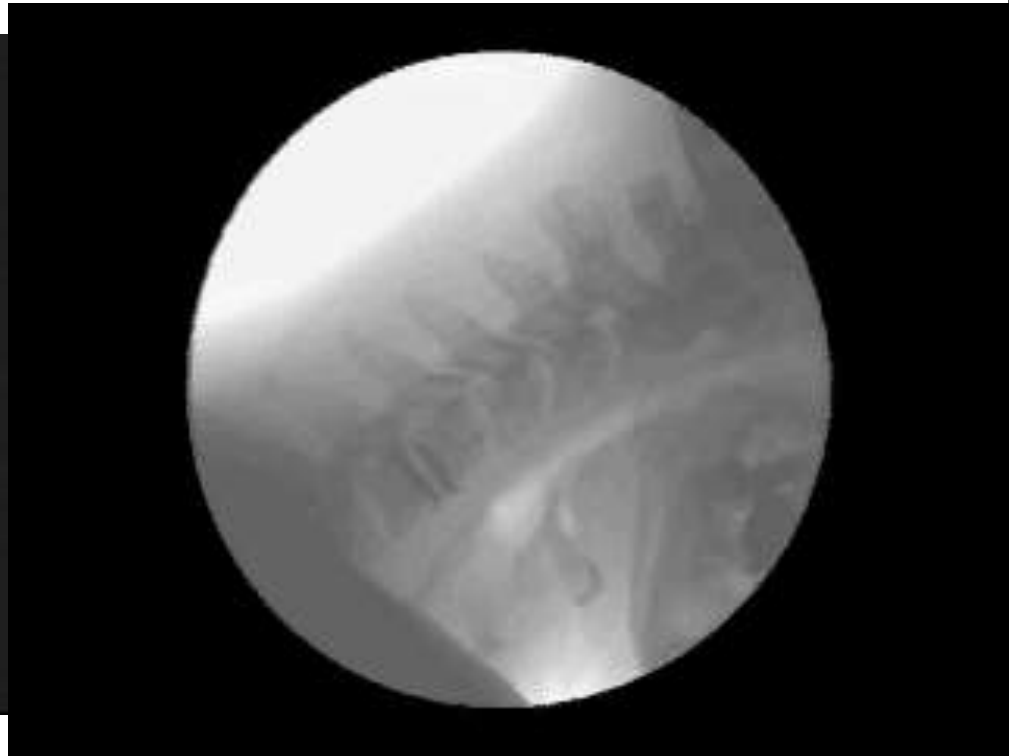
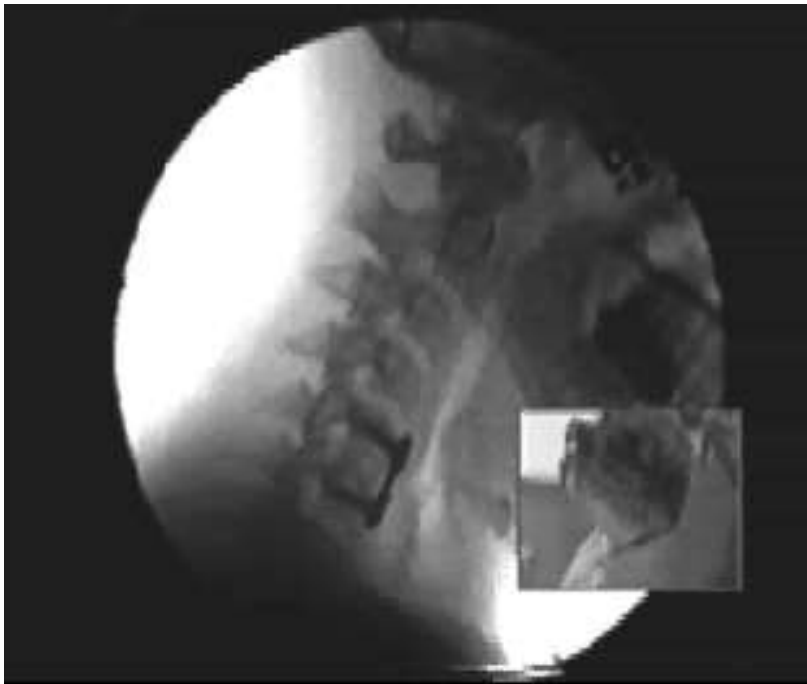## Implants



## Implants



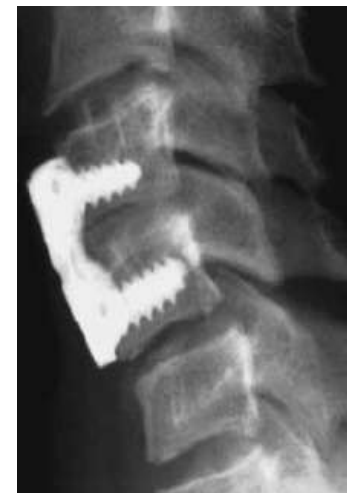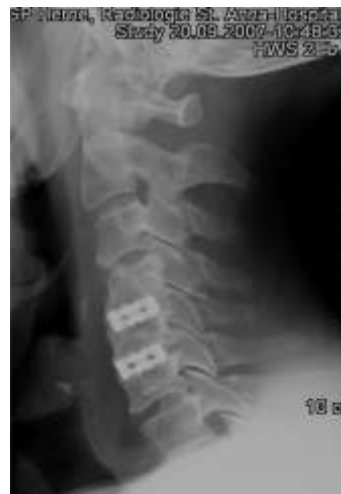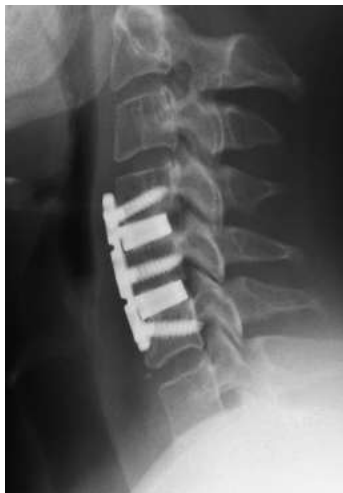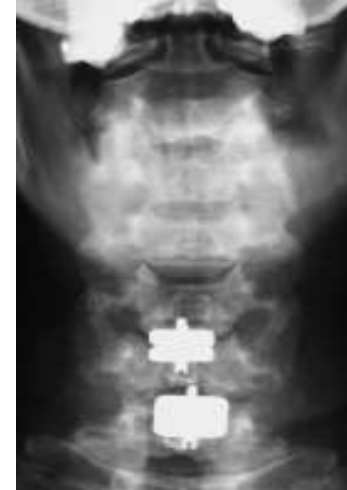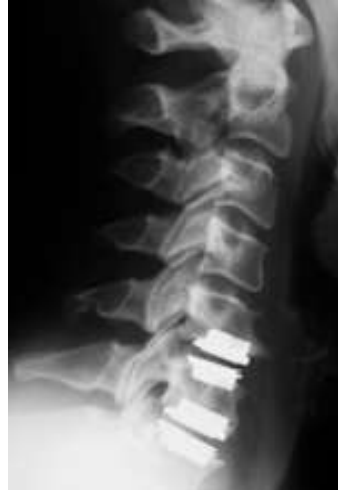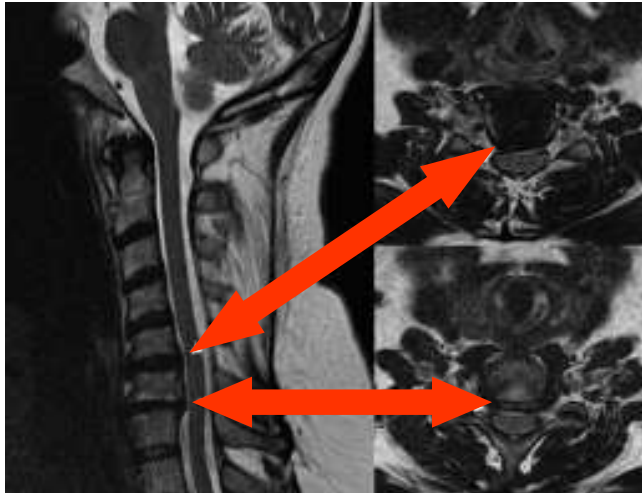
# Degenerative disease



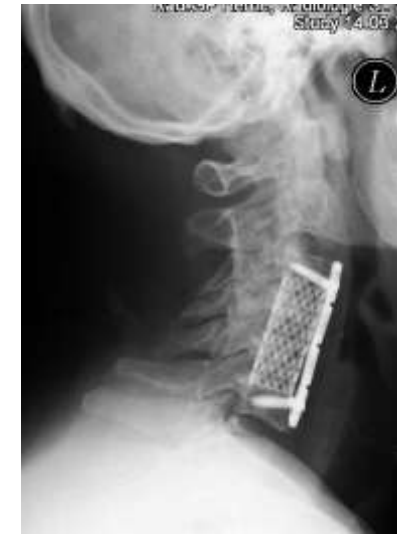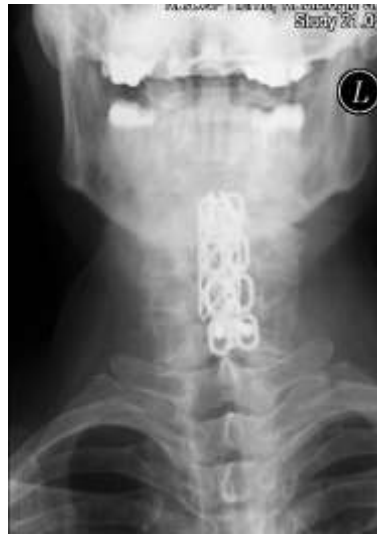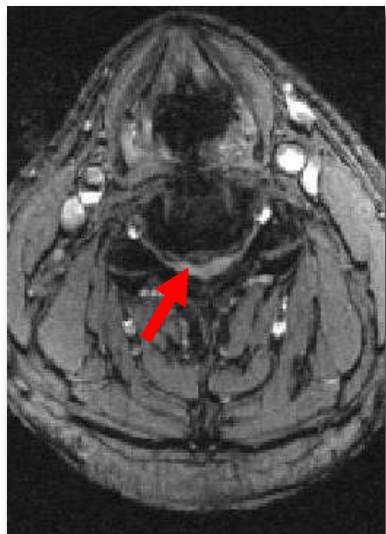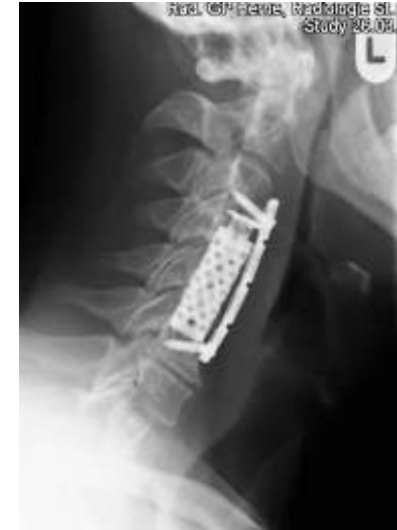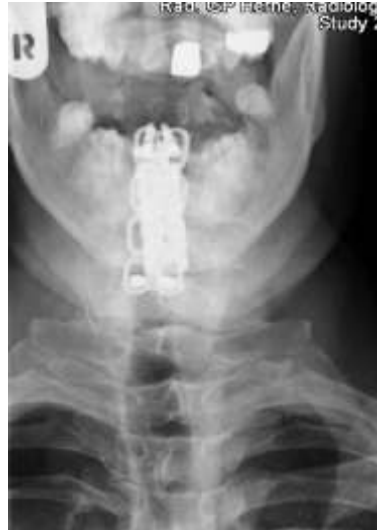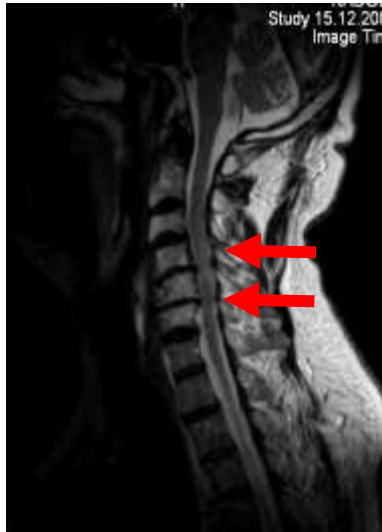**artificial cervical disc**



# Degenerative disease



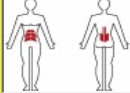



# Degenerative disease

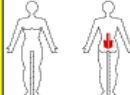
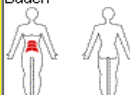






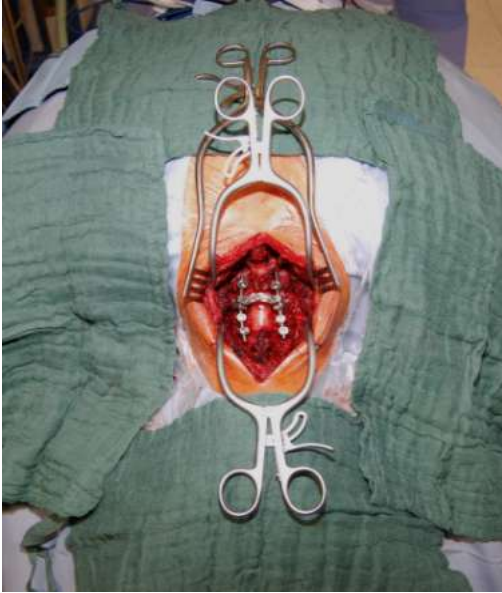
# Physiotherapy after spine surgery

# myoskelettal analysis

Muskelgruppe	isometr. Max. Kraft	Verän- derung in %	Dyn. Leist- ung	Kraftverhältnisse
Rücken 	AI 121 Nm	N/A		Bauch stärken 0,24 Rücken stärken 0,84 0,73
Bauch 	AI 88 Nm	N/A		Norm: 0,54
Drehung nach rechts 	AI 42 Nm	N/A		Links stärken 0,4 Rechts stärken 1,6 0,50
Drehung nach links 	AI 21 Nm	N/A		Norm: 1

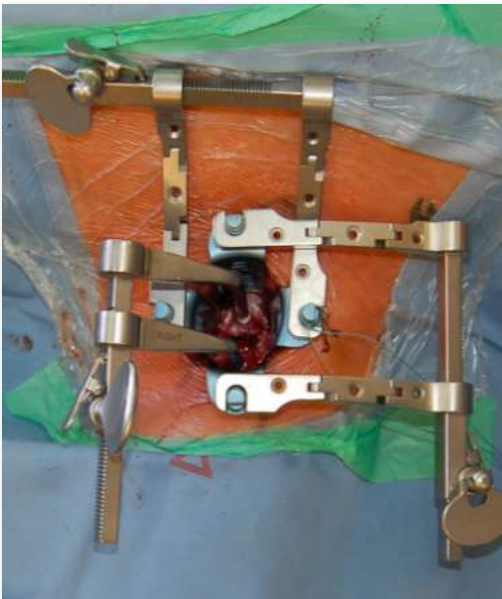
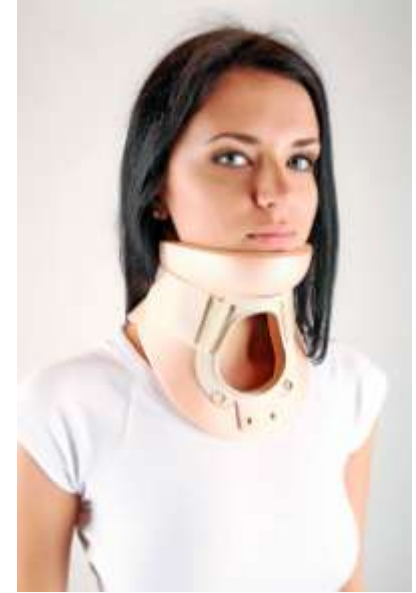Muskelgruppe	isometr. Max. Kraft	Kraft im Vergleich
Rücken 	AI 121 Nm	0% 200% 62%
Bauch 	AI 88 Nm	0% 200% 84%
Drehung nach links 	AI 21 Nm	0% 200% 26%
Drehung nach rechts 	AI 42 Nm	0% 200% 56%

Quelle der Referenzwerte: A. Denner - Muskuläre Profile der Wirbelsäule, Springer Verlag 1997



?

**Ask the surgant**

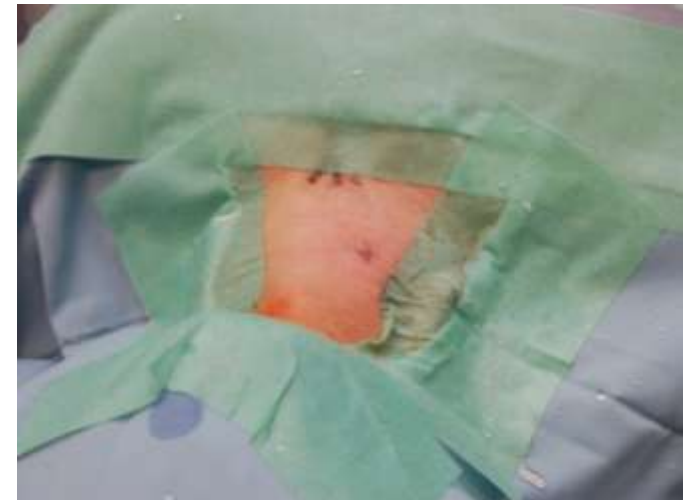


**2 weeks**





- **Early mobilisation**
- **Soft tissue protection**
- **Less post-operative pain**
- **Less scar tissue**
- **Less muscle damage**





# **3 phases of post-operative treatment**

**1. Supportive phase**

**2. Weaning phase**

**3. Rehabilitation phase**



# 3 phases of post-operative treatment

## 1. Supportive phase

- Brace has to be worn all the time
- Can be taken off for body hygiene

## 2. Weaning phase

## 3. Rehabilitation phase



# 3 phases of post-operative treatment

## 1. Supportive phase

## 2. Weaning phase

- Brace can be taken off for some time
- Patient decides when brace will be taken off for longer periods

## 3. Rehabilitation phase



# 3 phases of post-operative treatment

## 1. Supportive phase

## 2. Weaning phase

## 3. Rehabilitation phase

- No brace needed





# Patient management

- **Explain why brace is needed**
- **Explain handling with the brace**
- **Show patient how to behave**
- **Explain ADLs**
- **Try to support patient so he is not afraid**

**Patient has to feel well informed**

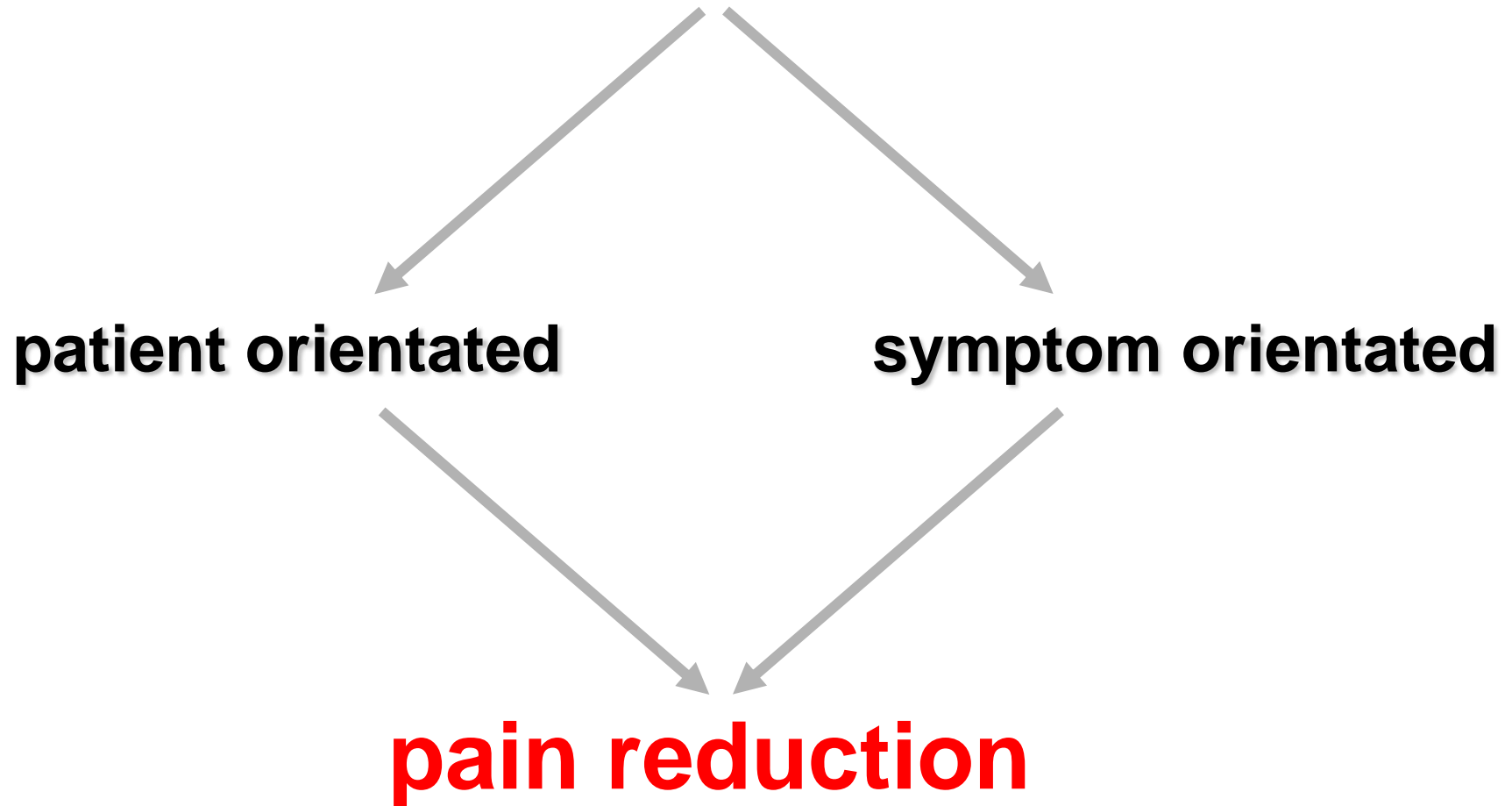


- brace can be taken off for showering etc.
- After MIS movement of neck is allowed
- Daily chores are allowed
- Heavy lifting is forbidden
- Extreme neck rotation is forbidden

**Patient should listen to signals**  
**His own body will tell him if he is behaving right**

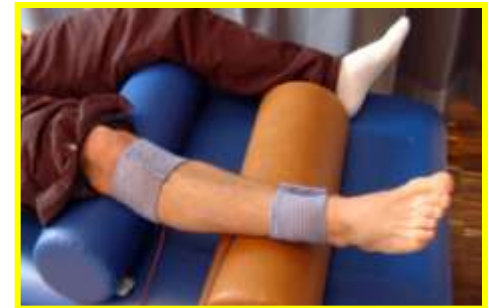
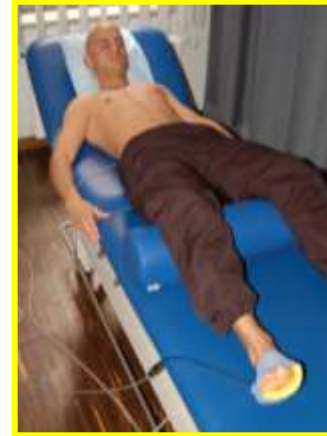
## Individual therapy



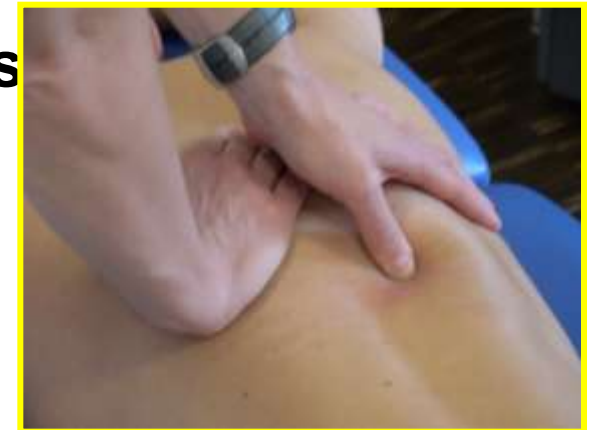## physical therapy

- pain reduction
- muscle electrotherapy



## Correction of pain avoiding posture

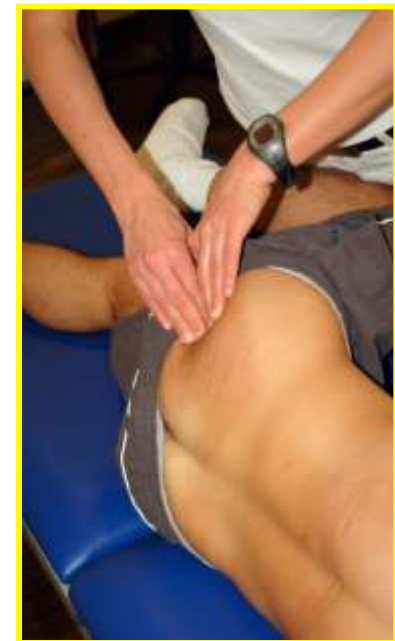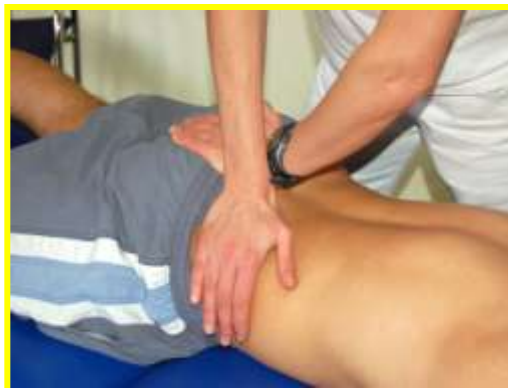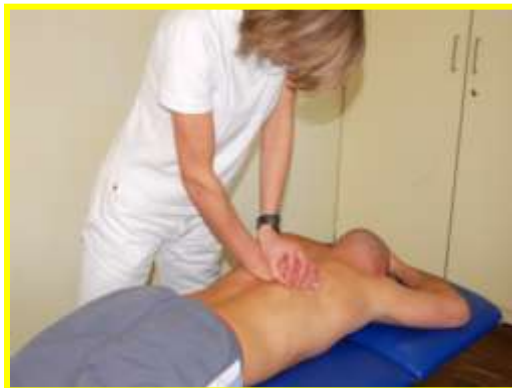- Massage of painful muscle groups
- stretching shortened muscles
- gait pattern correction



## Scar tissue softening


## Do not forget the rest of the spine

- thoracic/lumbar spine
- ileosacral joints
- M. Piriformis

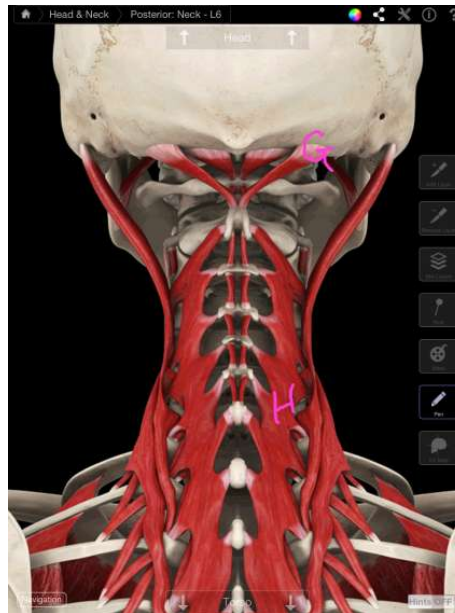





## Activation of segmental muscles of the spine

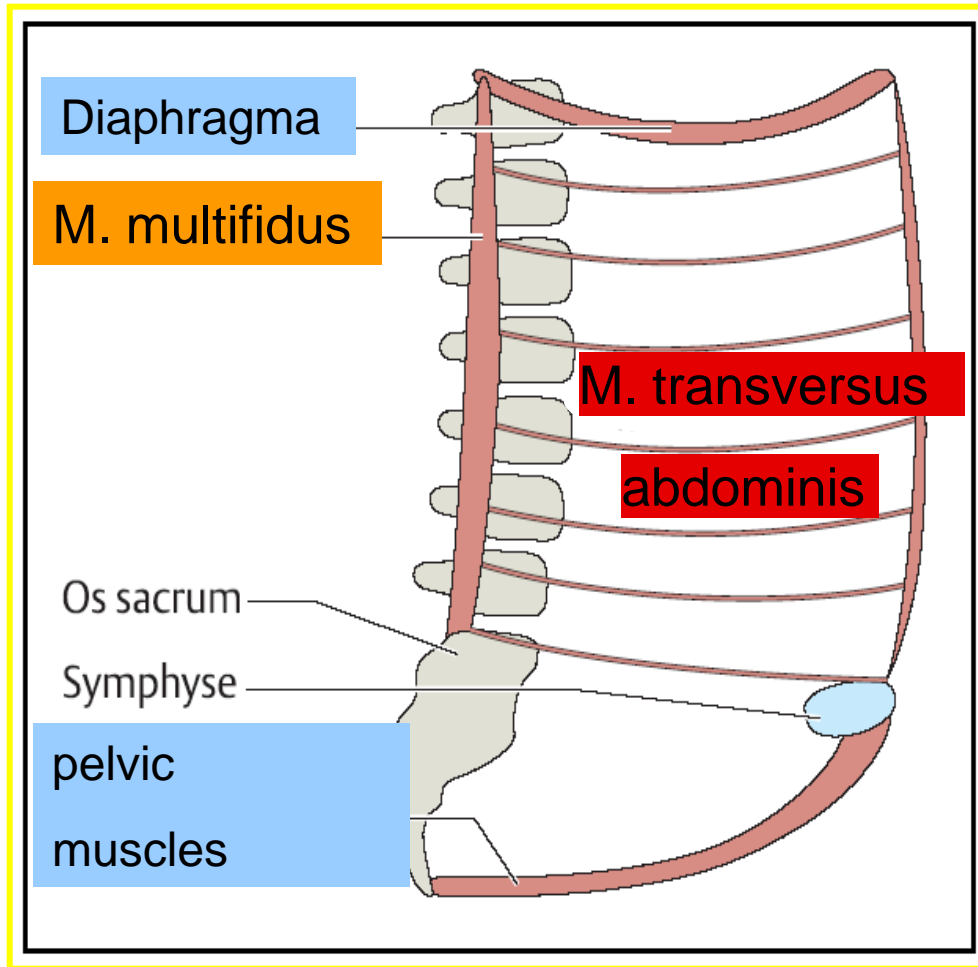


**pain reduction**



## Characteristics

- **Monosegmental**
- **located at the dorsal aspect of the spine**
- **short lever arm  $\Rightarrow$  low torque**
  -  no movement generated**
- **axial stabilization of the facette joint:**
- **$\Rightarrow$  spine stabilization**
  - $\Rightarrow$  Motoric movement controll**



**Active stabilization**

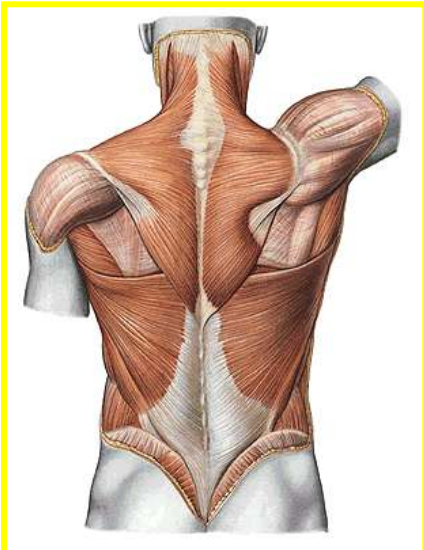
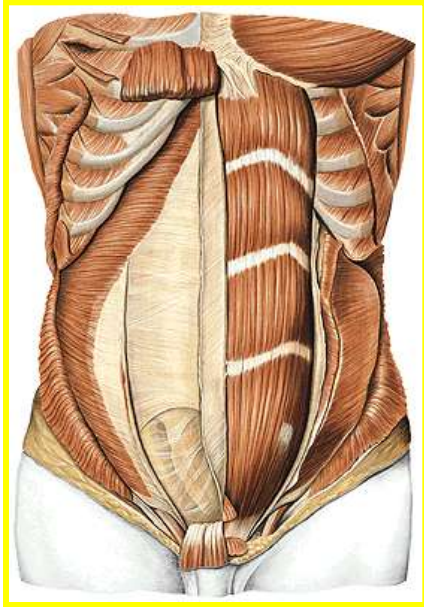
**Stabilization of spine via abdominal pressure**

**Important to maintain intraabdominal pressure**

At the cervical spine stabilization via segmental muscles

## Characteristics

- **polisegmental**
- **located at the dorsal and ventral aspect of the spine**
- **long lever arm  $\Rightarrow$  high torque**  
**cause movement**
- **no segment segmental stabilization**



M. rectus abd.

M. obliquus abd. ext.

M. obliquus abd. int.

M. semispinalis

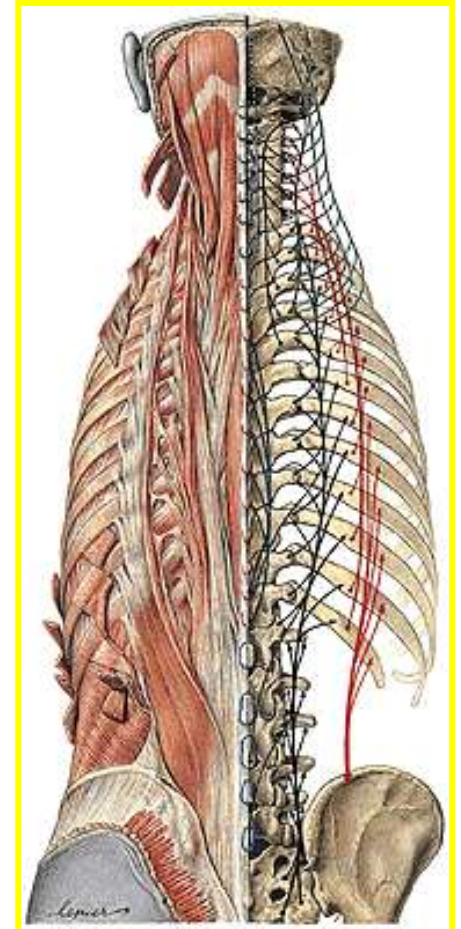
M. iliocostales

M. splenii

M. scaleni

M. latissimus dorsi

M. quadratum lumborum







# Important for stable movement

ST. ELISABETH GRUPPE   
KATHOLISCHE KLINIKEN RHEIN-RUHR

**Segmental muscles have to be activated  
before movement muscles.**

1. Activation of segmental muscles prior to movement

## **Segmental stability**

2. Keeping segmental stability stable while activating movement muscles.

## **Global stability**

3. Learning to use global stability in every day chores.

## **Functional stability**

**Supportive phase**

**Weaning phase**


**Rehabilitation phase**

**segmental stability**

**global stability**

**functional stability**

**pain while training:**



**insufficient segmental stability**























