

Diseases of the cervical spine

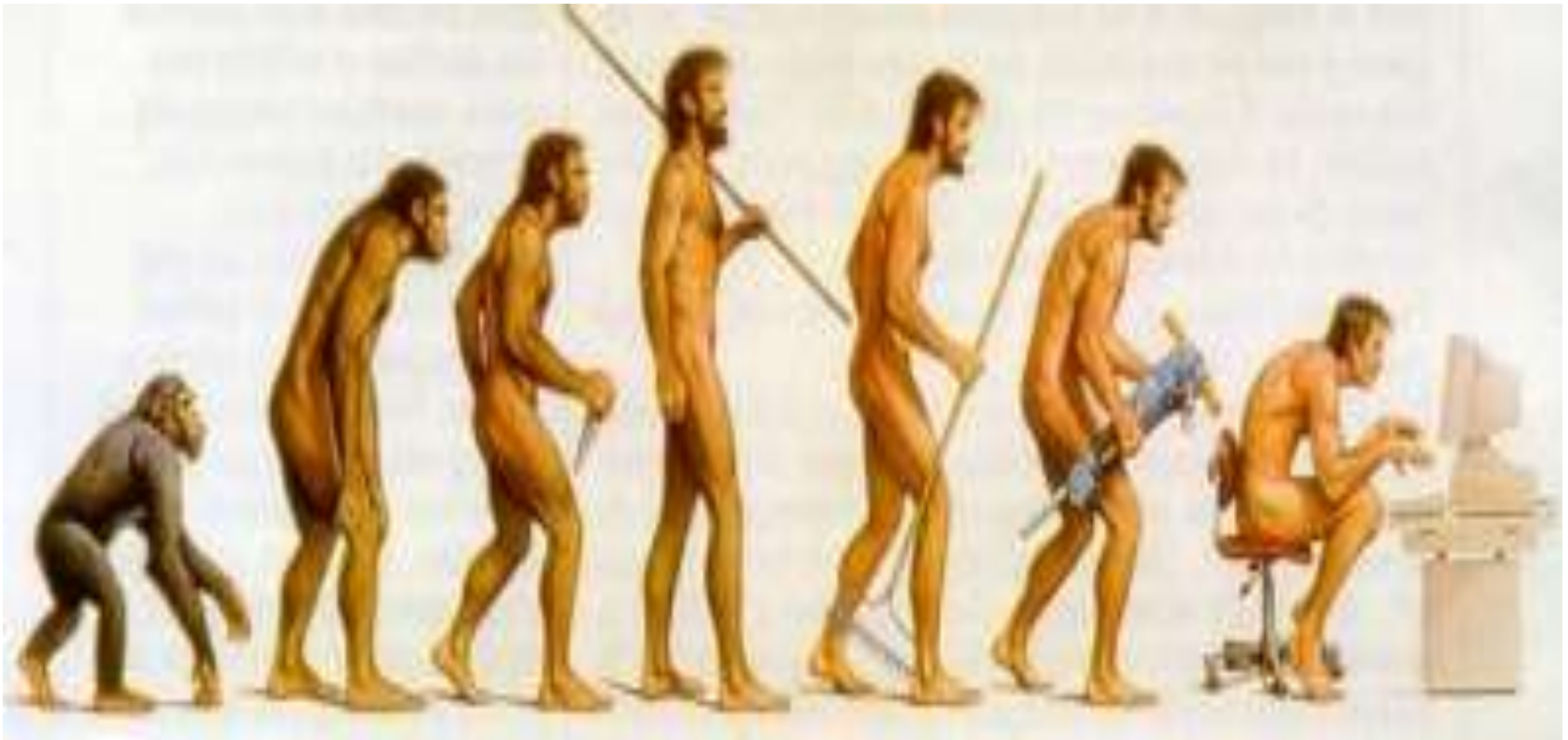
Dr. Athanasios Giannakopoulos

Center for pain-therapy and spine surgery
Priv.-Doz. Dr. med. habil. Sebastian Ruetten

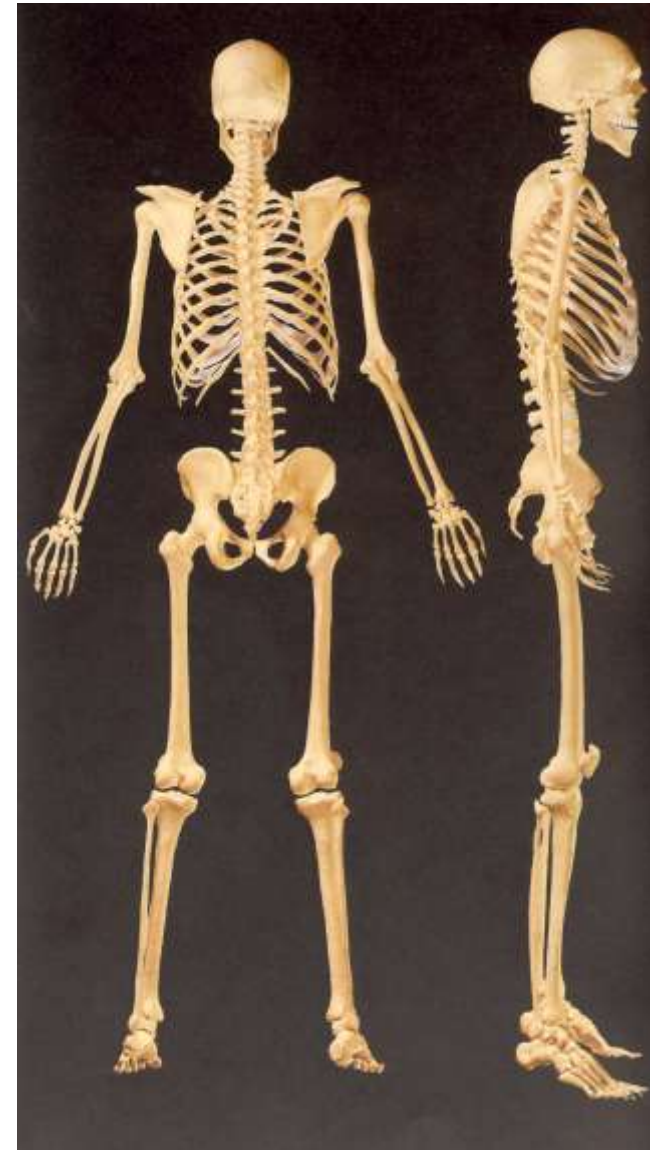

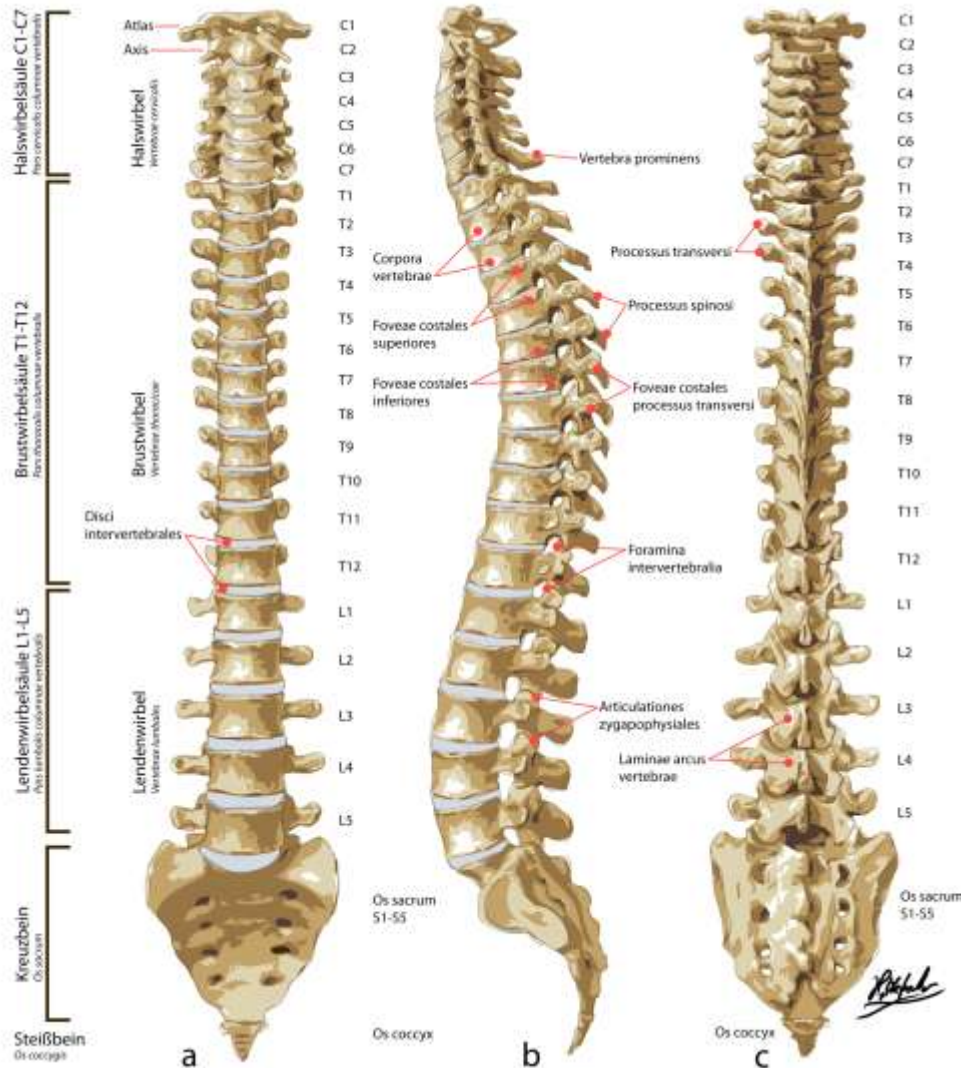Center for orthopedic surgery and traumatology
St. Elisabeth group
Director: Prof. Dr. med. Georgios Godolias

St. Anna Hospital Herne 
Universitätsklinikum
Marienhospital Herne 
Marien Hospital Witten 



- Bearing structure for the head and extrimities
- Protects the myelon
- Bearing of the ribs
- Shock absorbing function



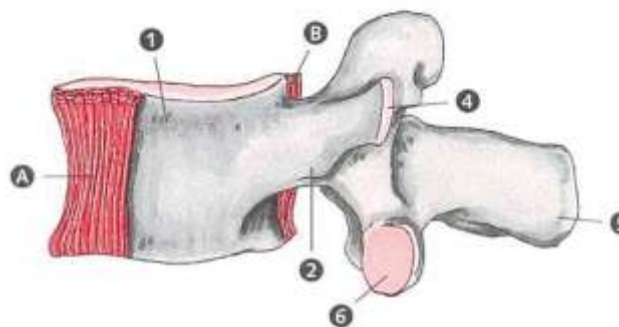
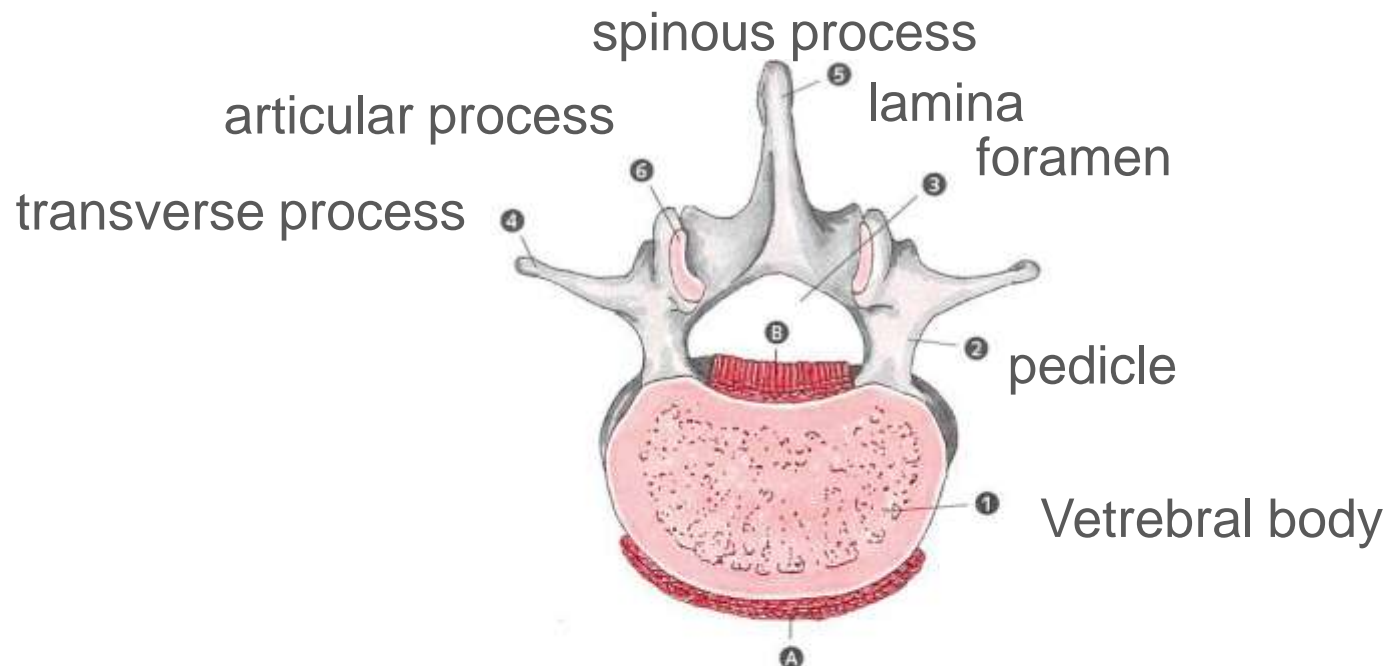


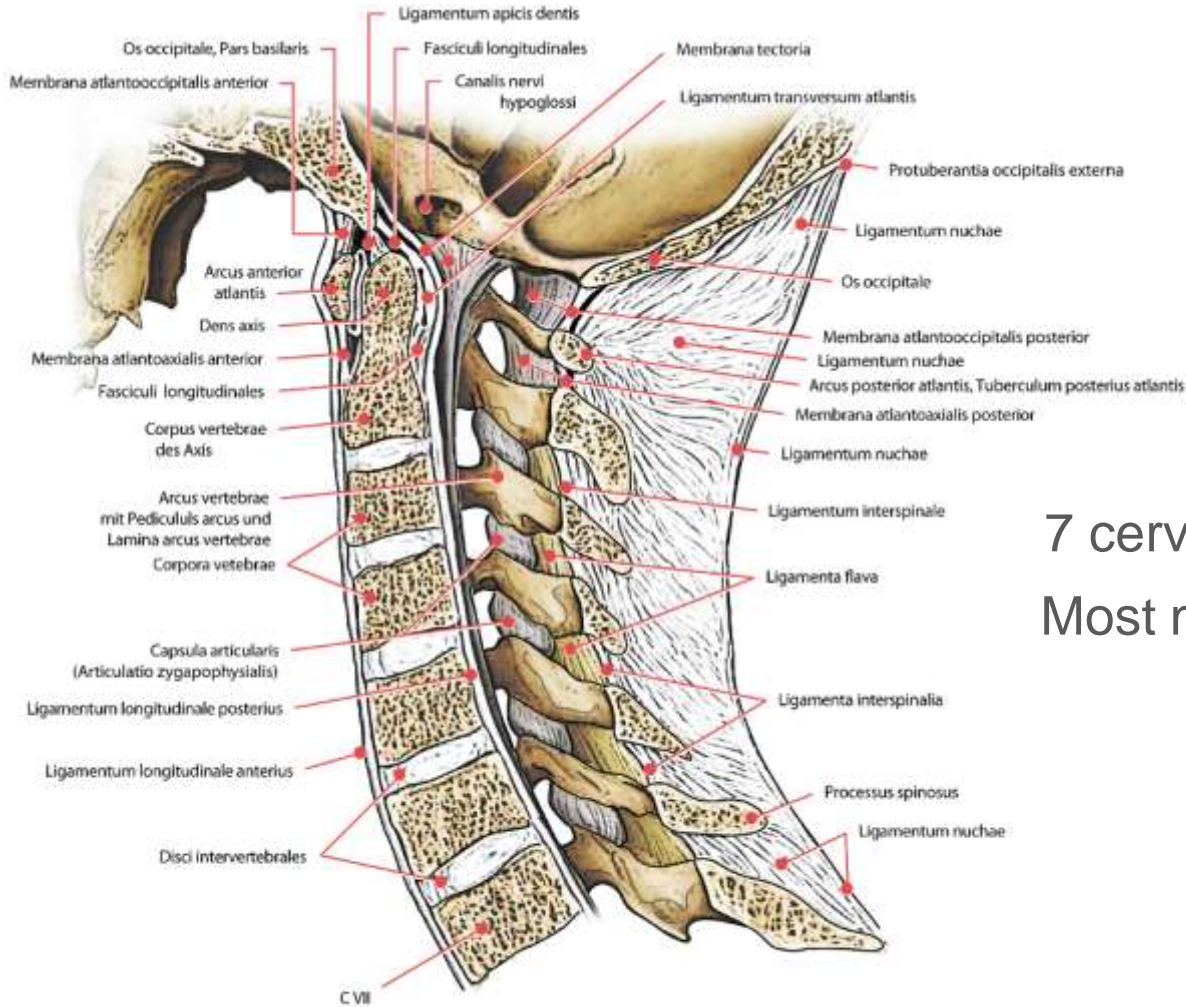
Cervical spine (7)

Thoracic spine (12)

Lumbar spine (5)

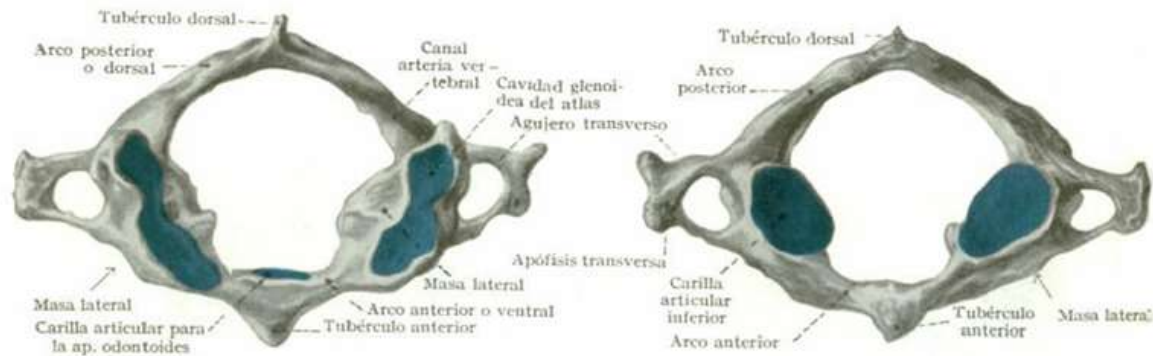
Sacrum (5)





7 cervical vertebrae

Most mobile part of the spine

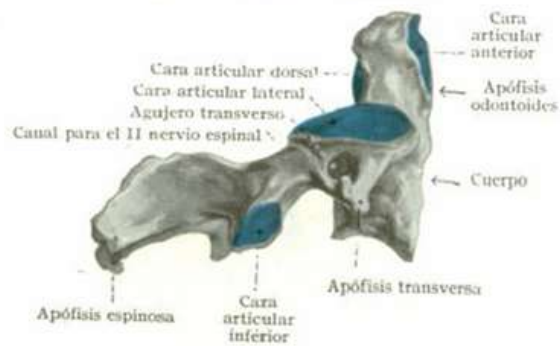


Atlas

Superficie craneal o superior

Atlas

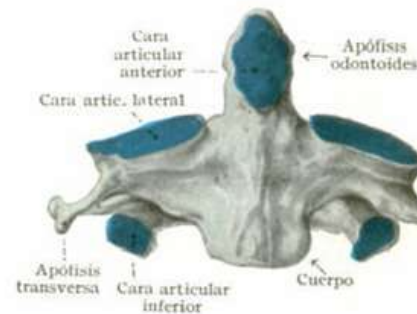
Superficie caudal o inferior



Axis (epistrophus)

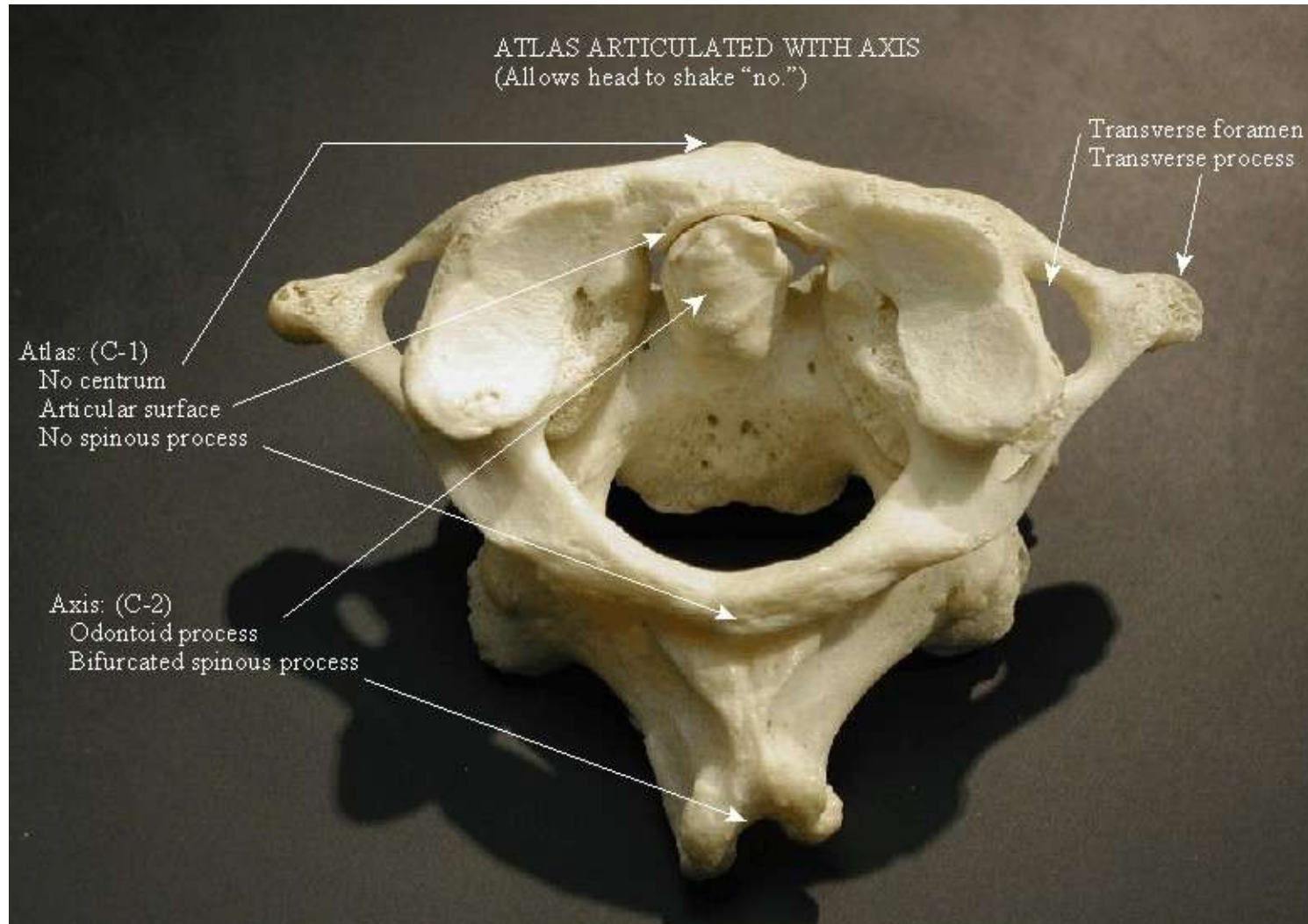
Lado derecho

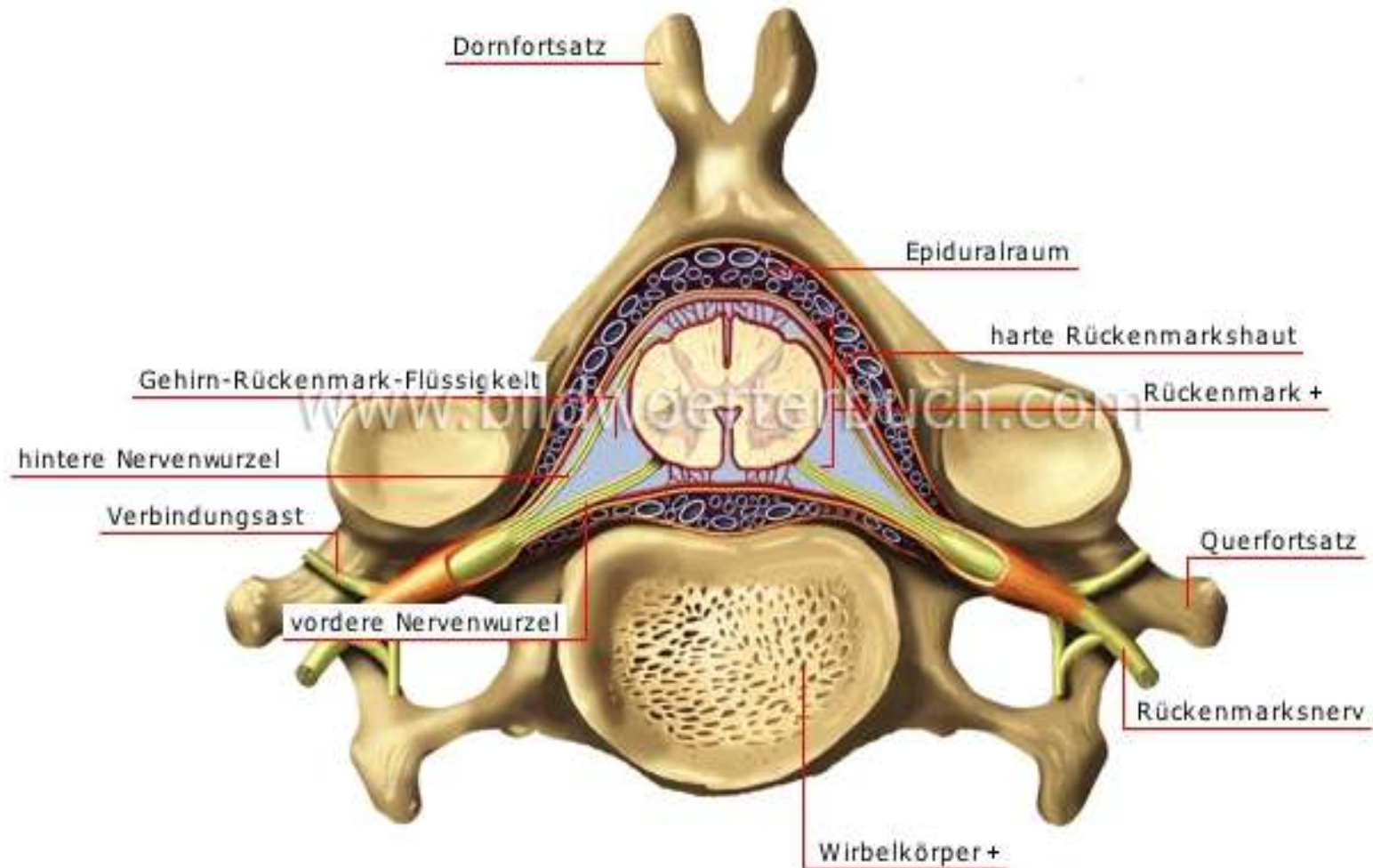
(Las superficies articulares recubiertas de cartilago hialino están teñidas de azul)

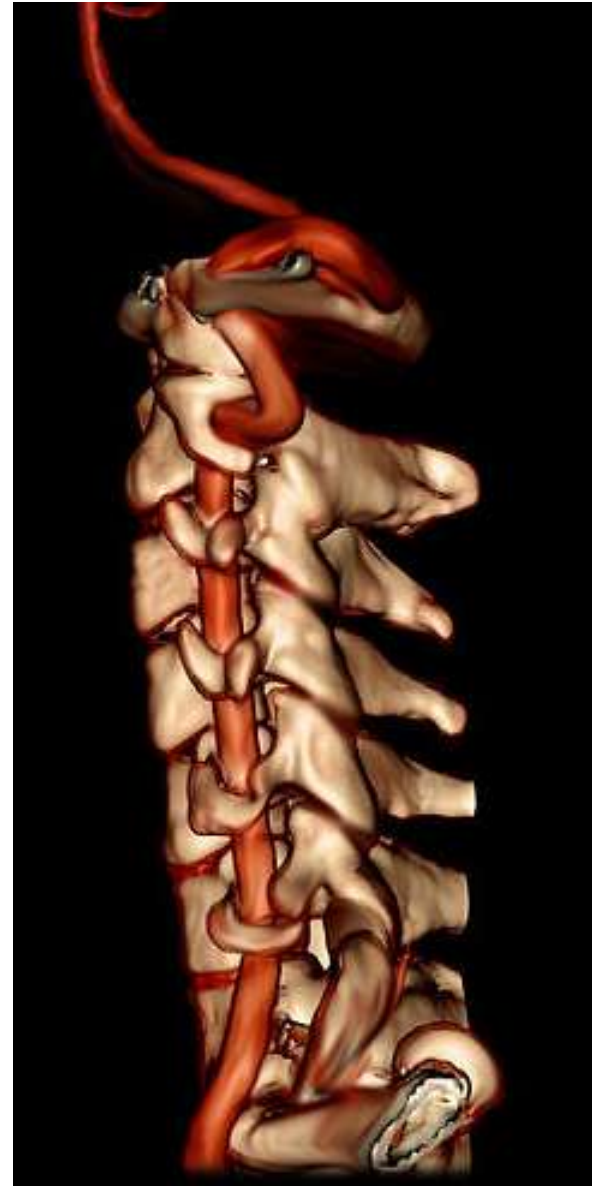
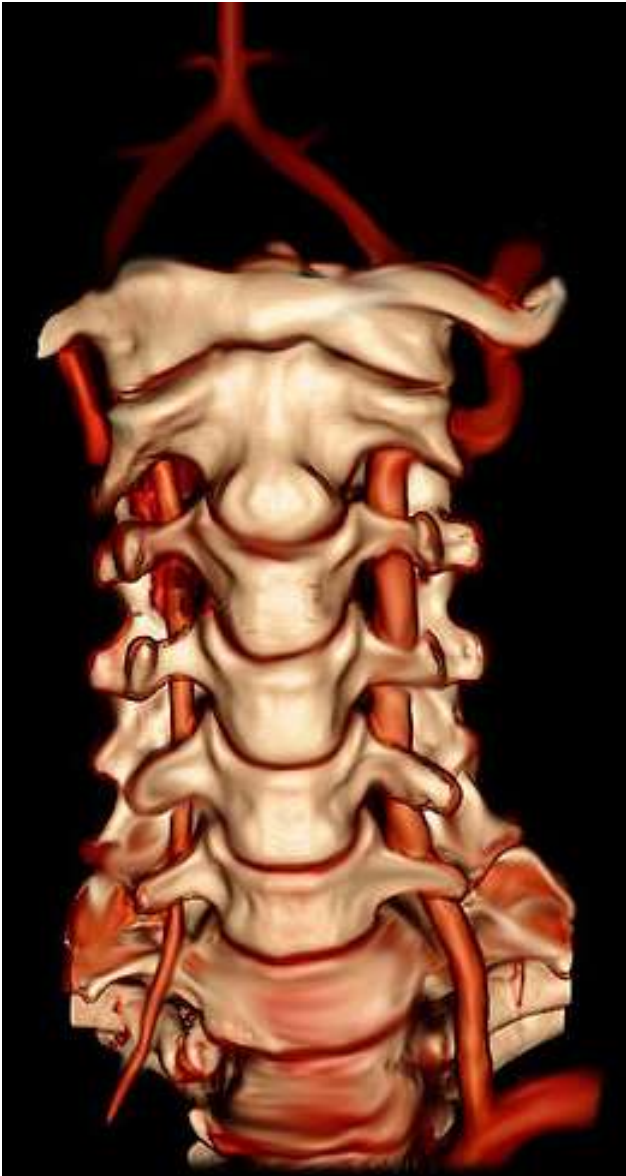
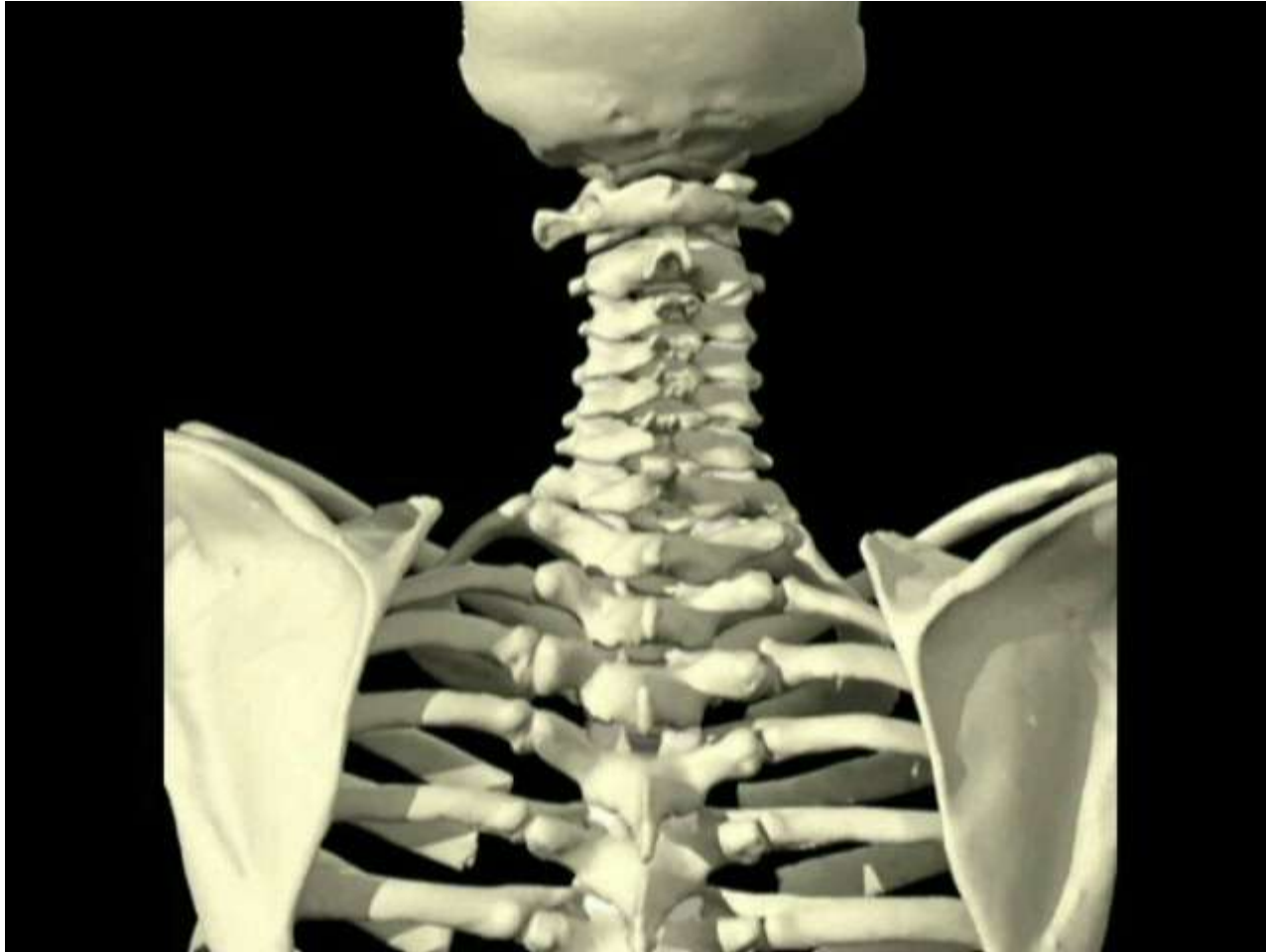Axis (epistrophus)

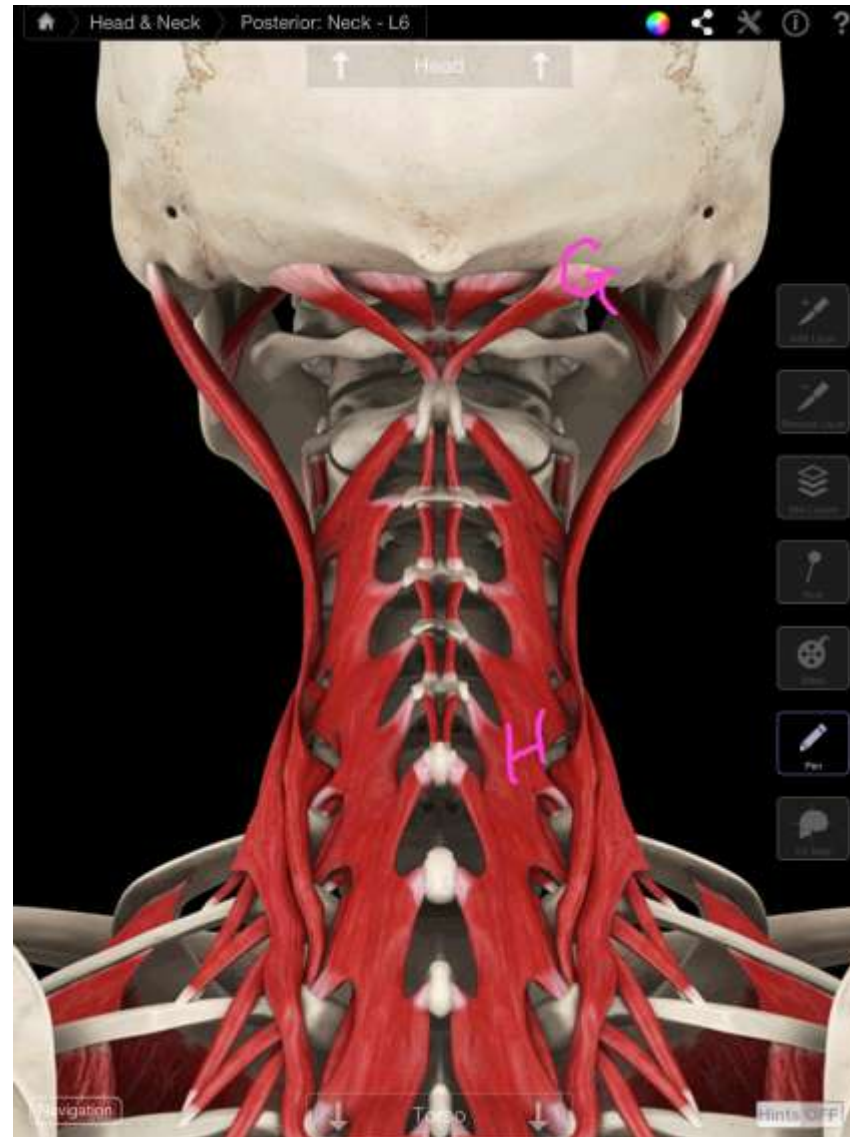
Superficie ventral o anterior



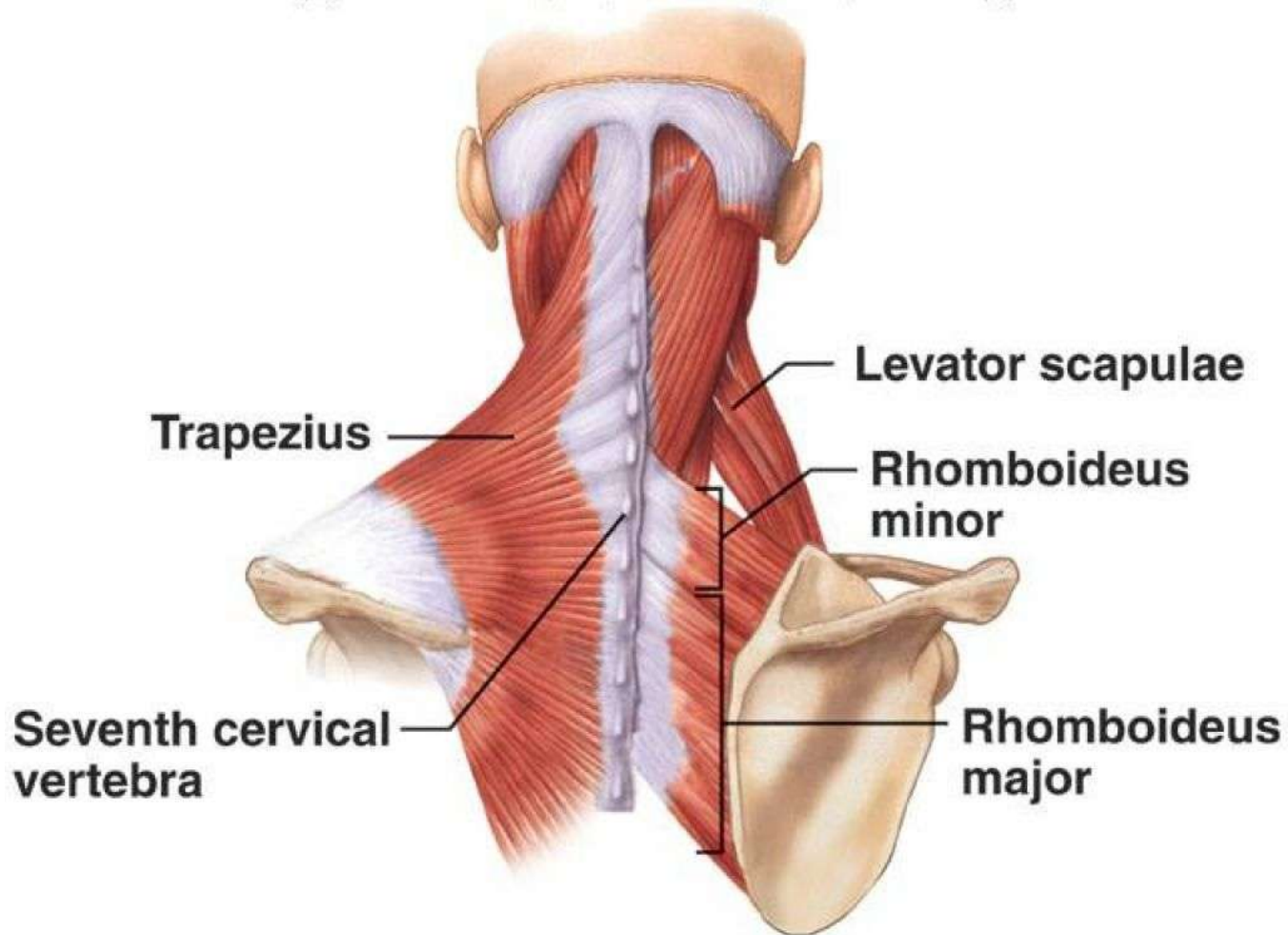


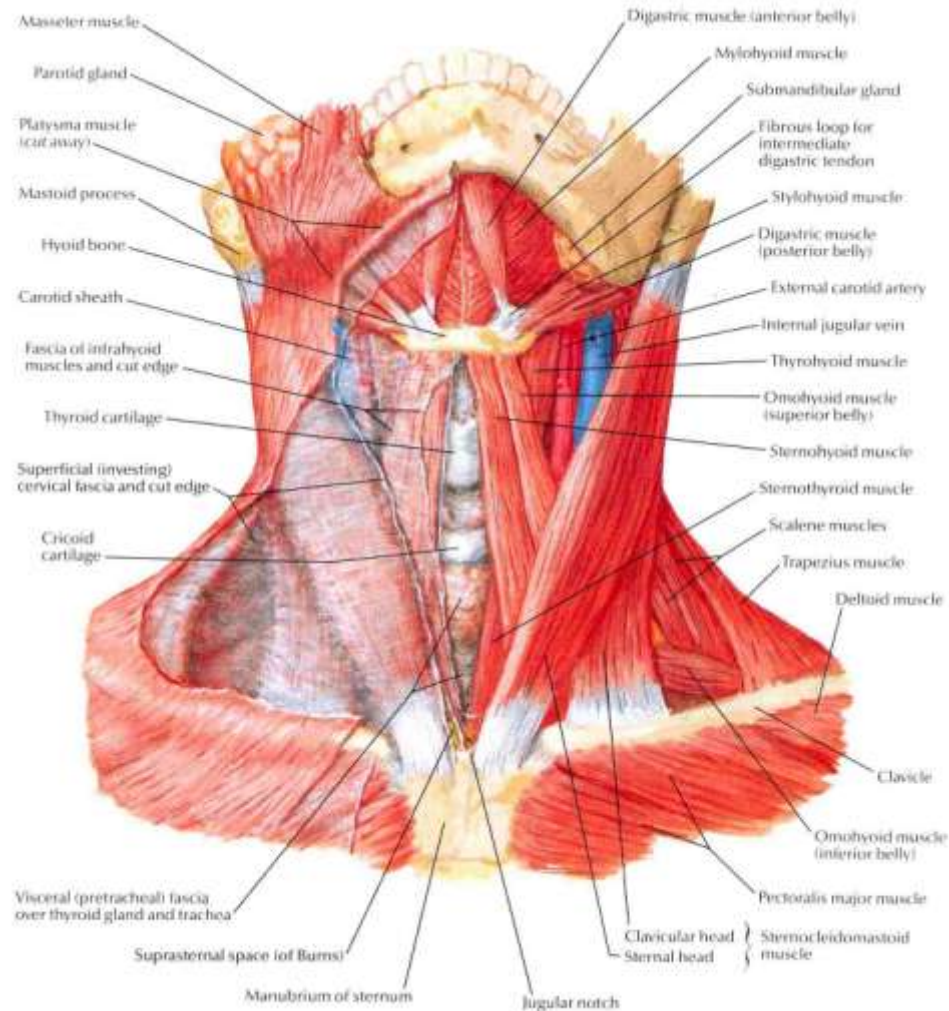




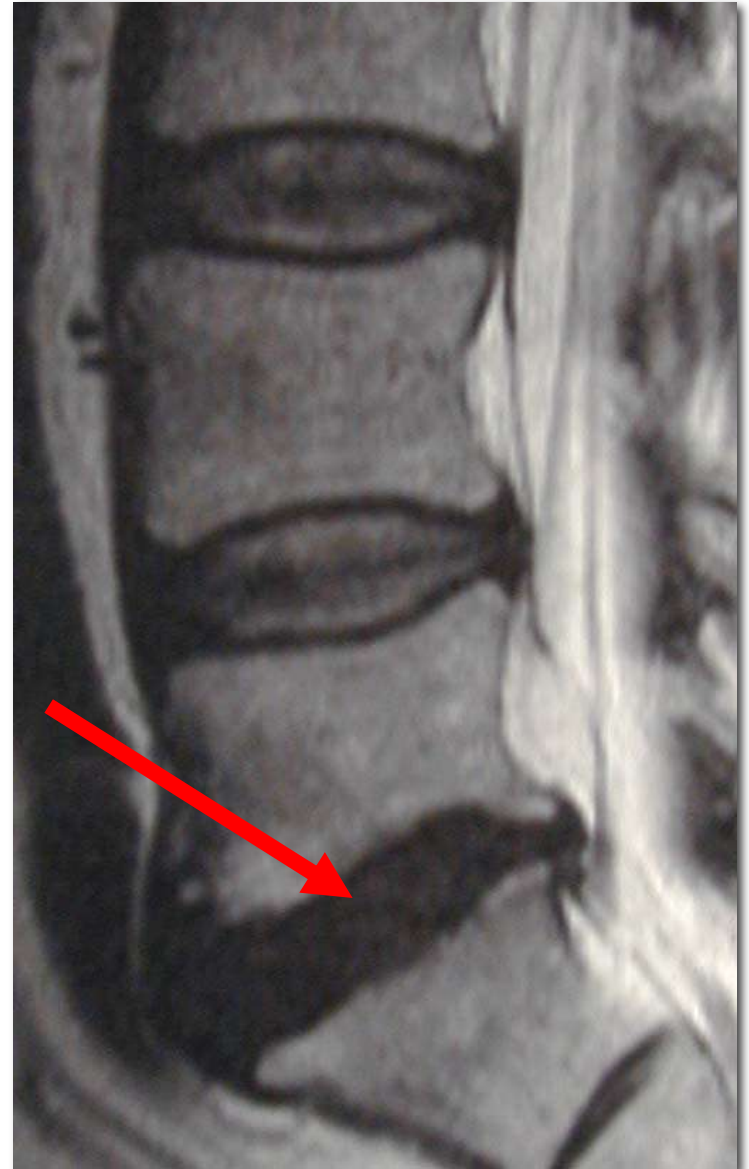
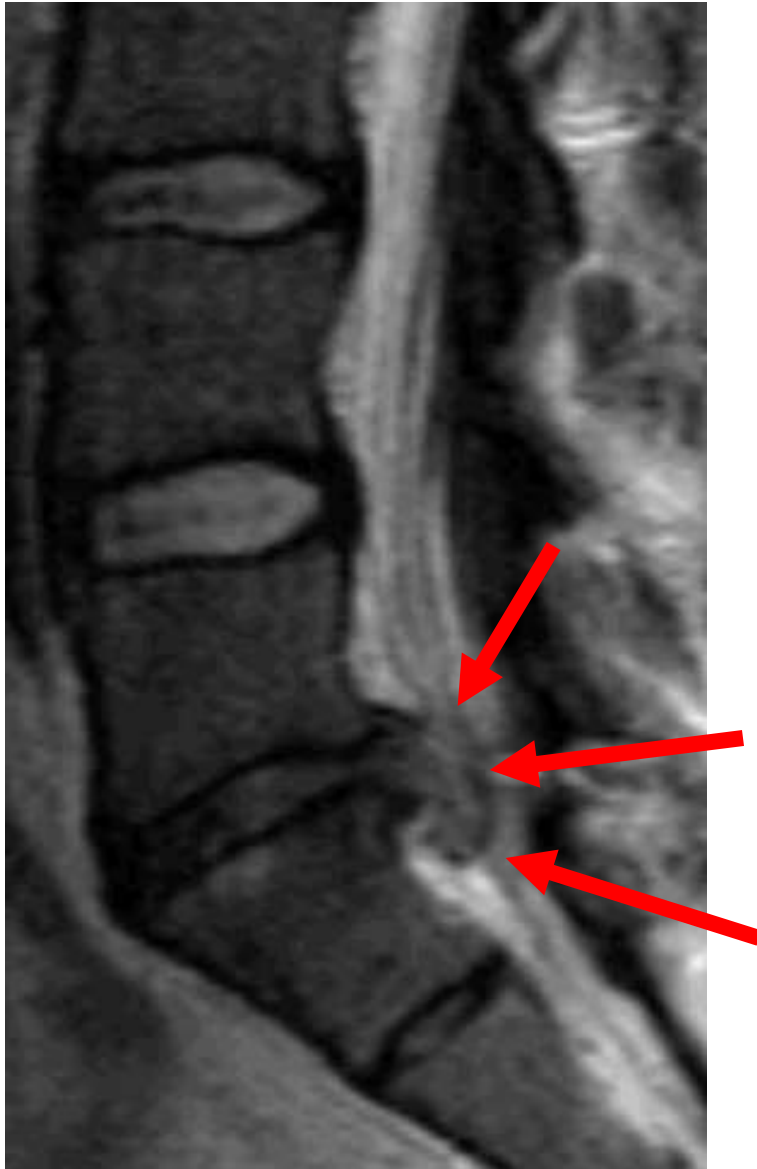

Copyright © The McGraw-Hill Companies, Inc. Permission required for reproduction or display.





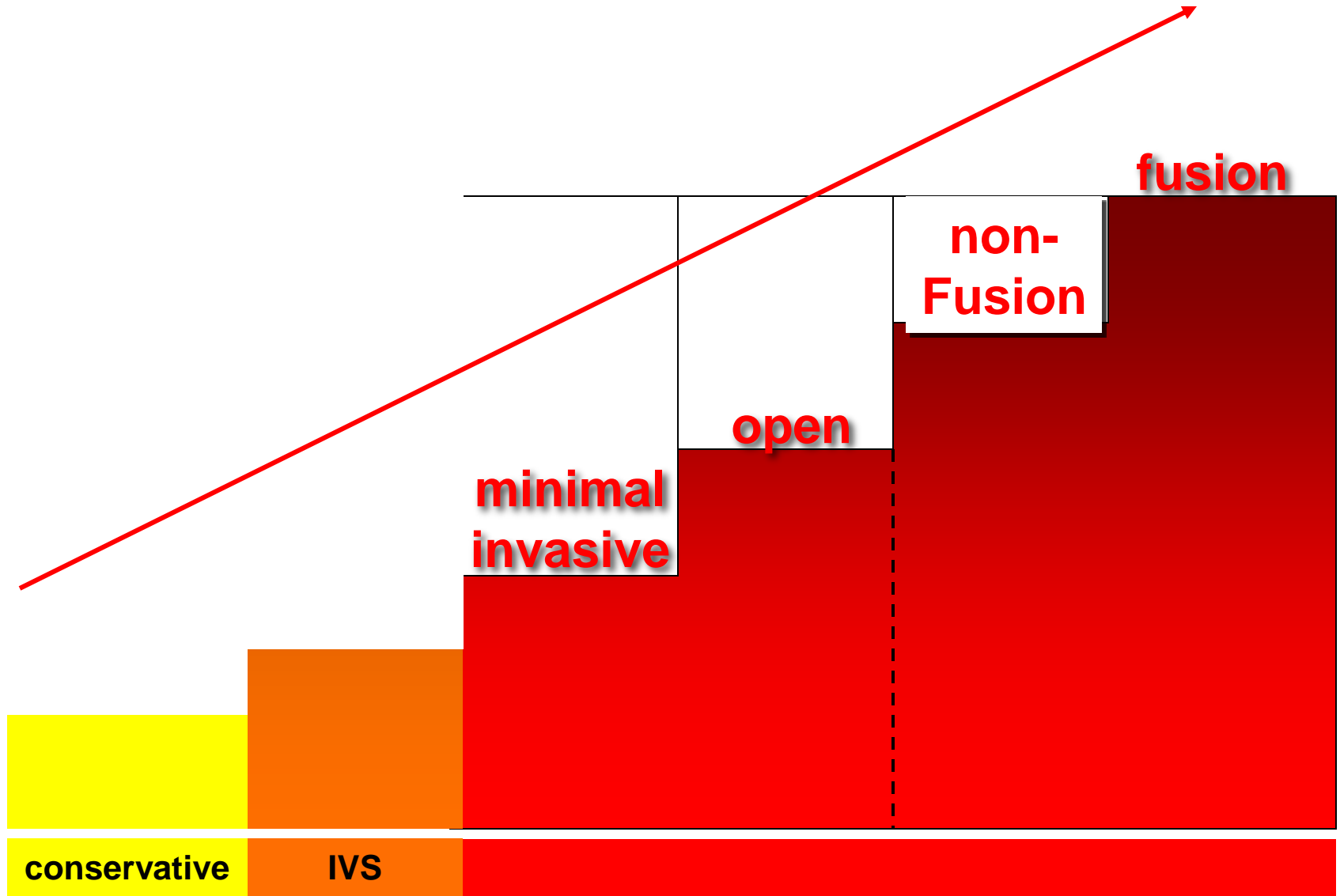
Conservative treatment or surgery?





Conservative treatment or surgery?

ST. ELISABETH GRUPPE
KATHOLISCHE KLINIKEN RHEIN-RUHR

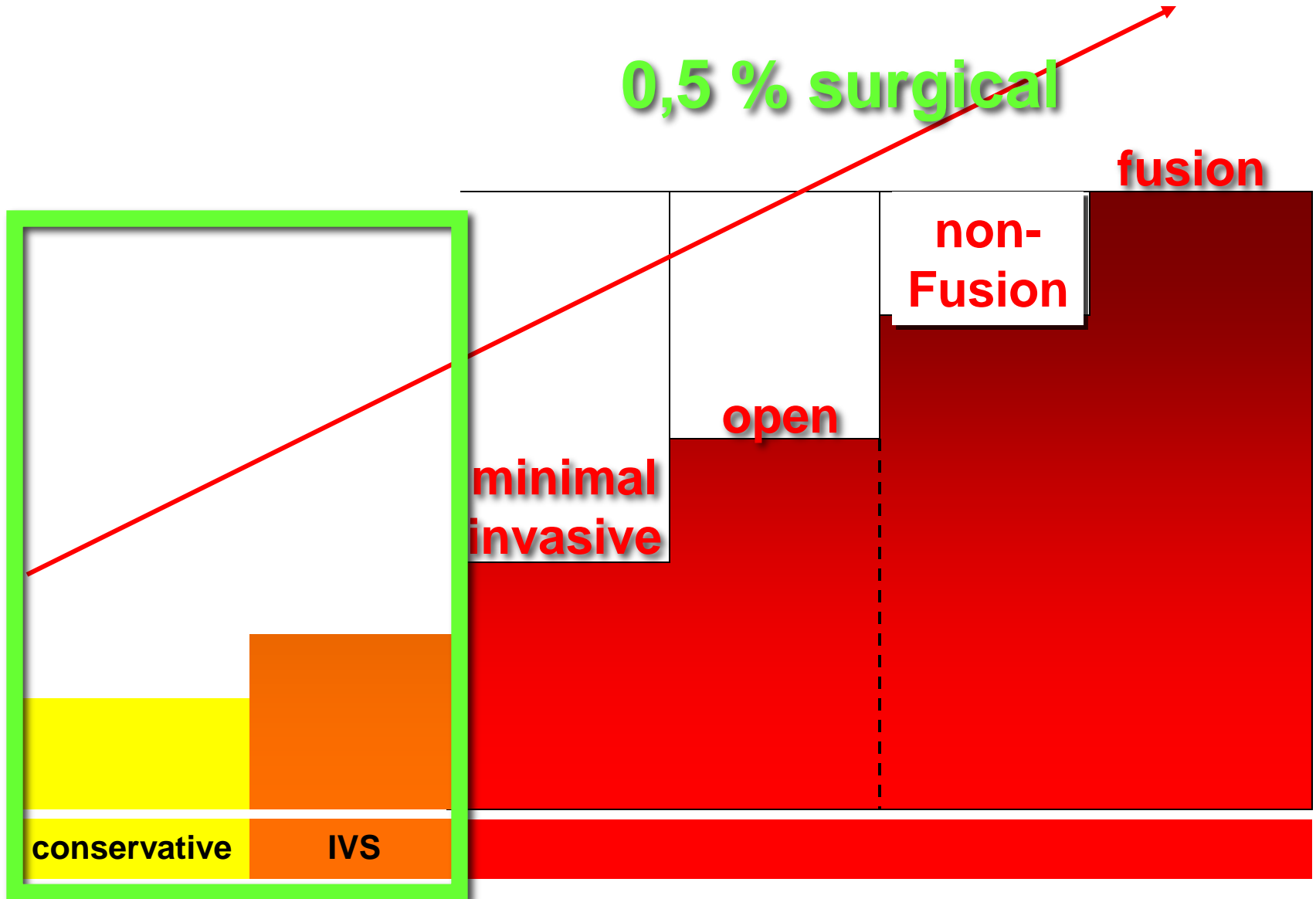


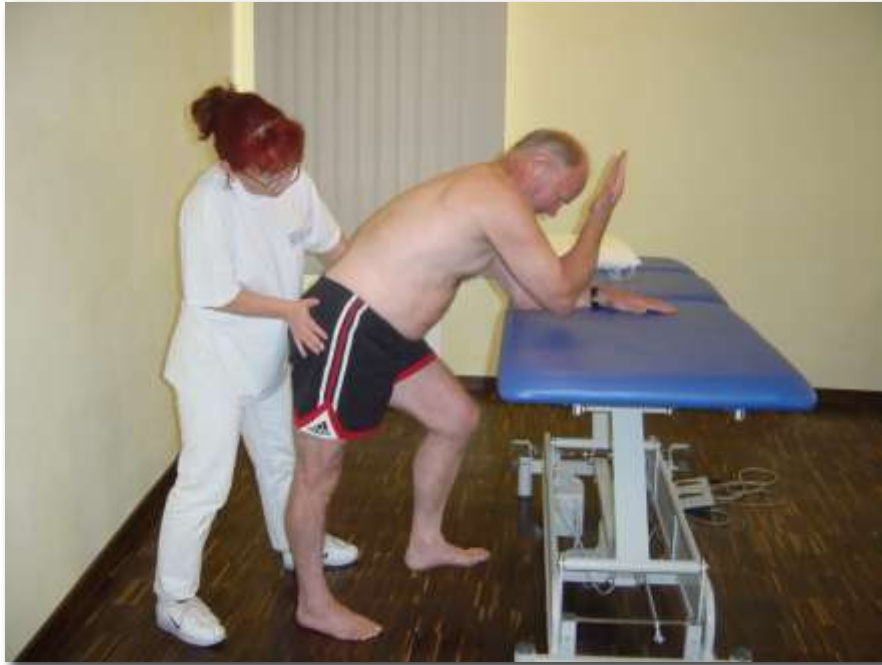

Conservative treatment or surgery?

ST. ELISABETH GRUPPE
KATHOLISCHE KLINIKEN RHEIN-RUHR

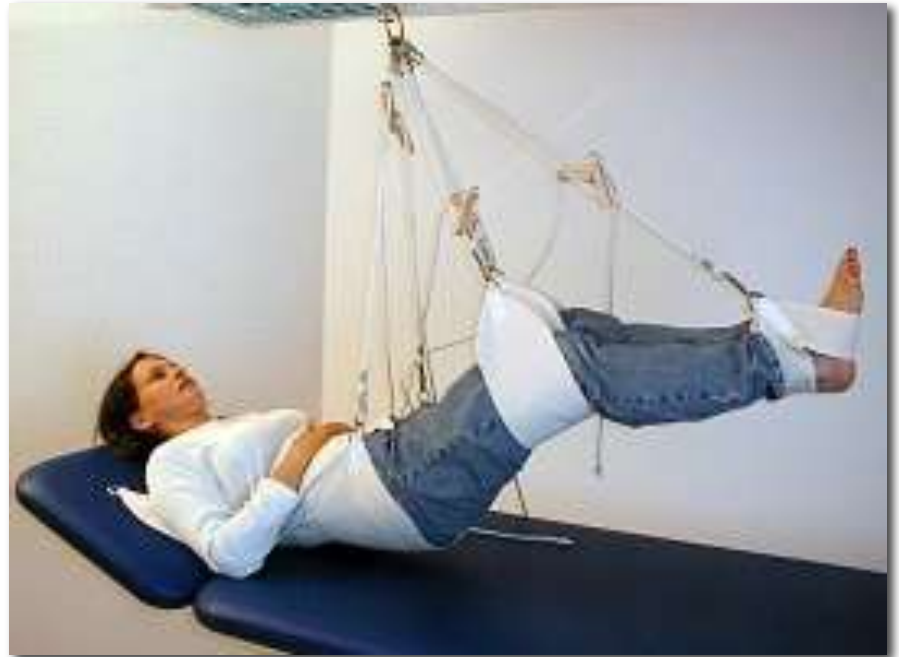0,5 % surgical





physiotherapy


physical therapy



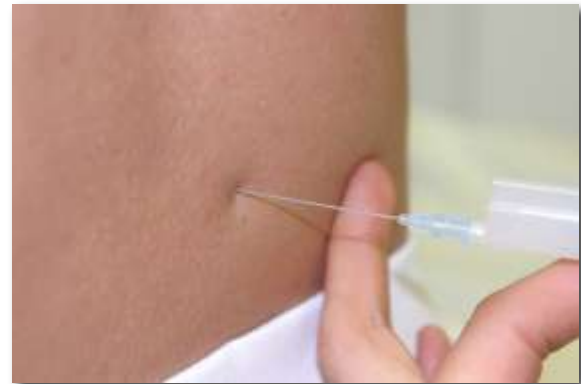drugs



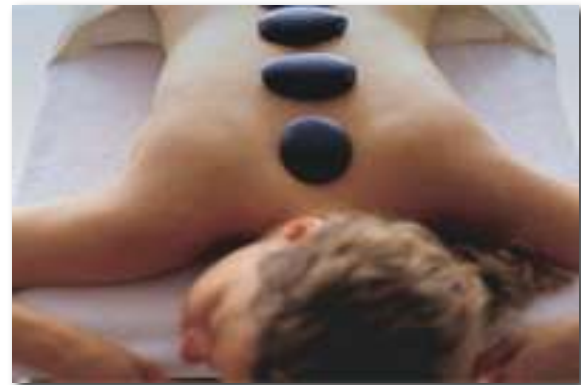acupuncture



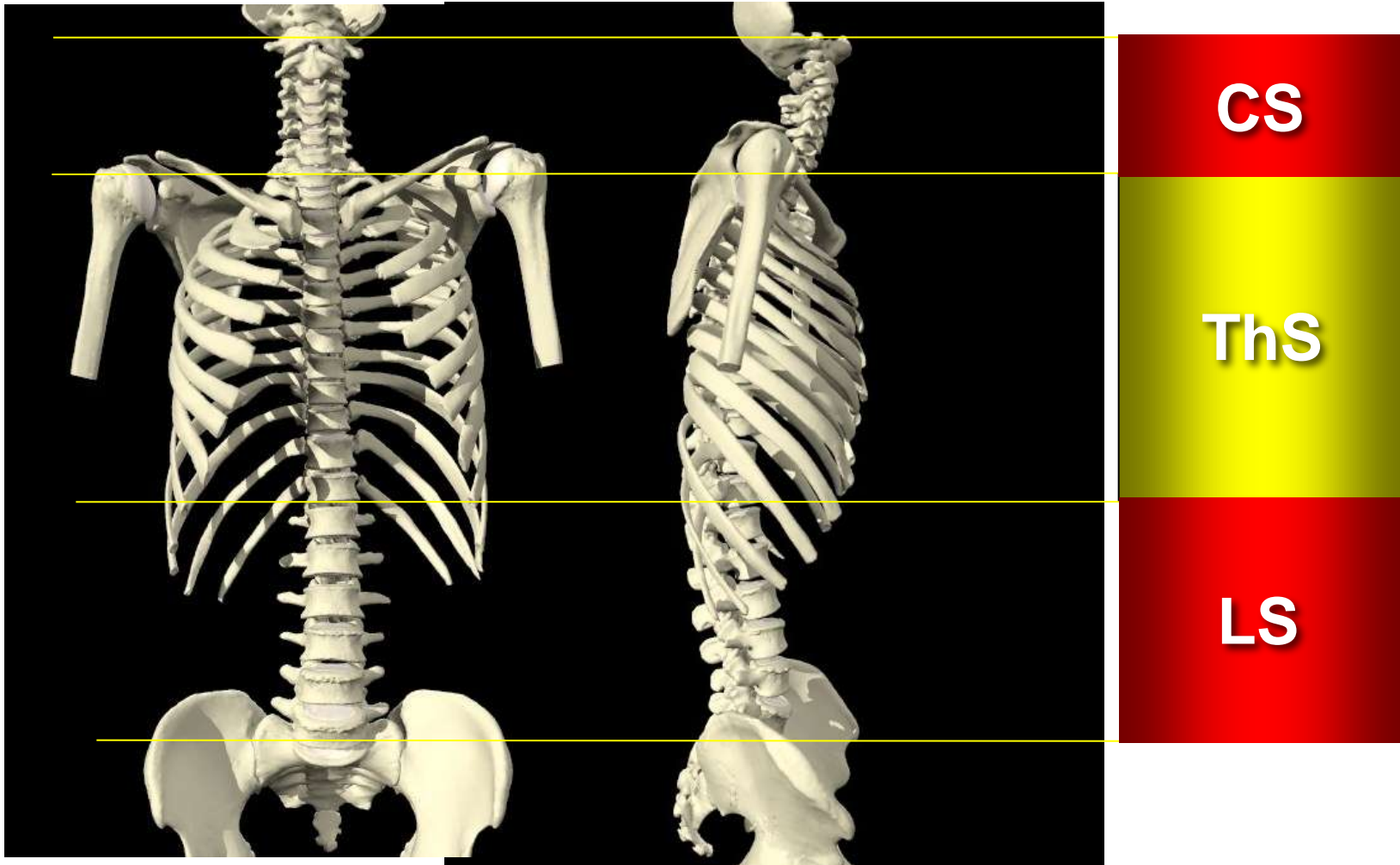
injections



others



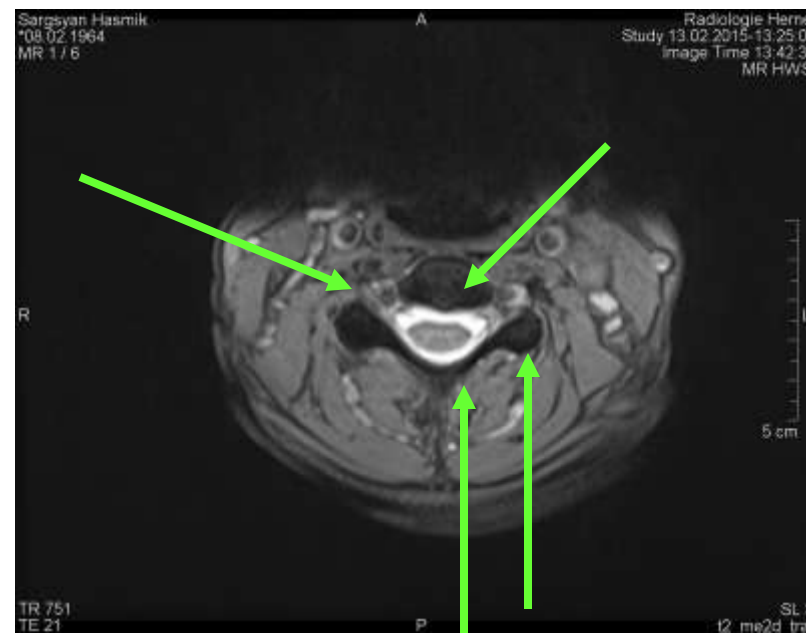
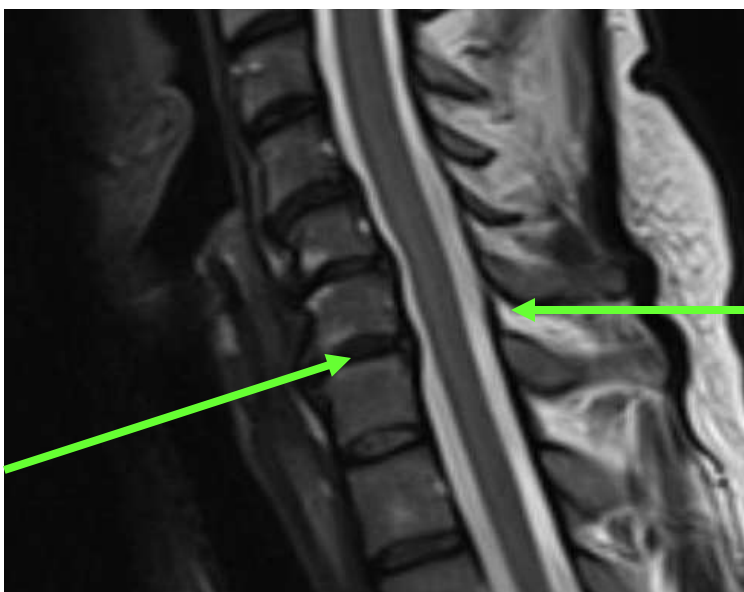
C-Arm Injections

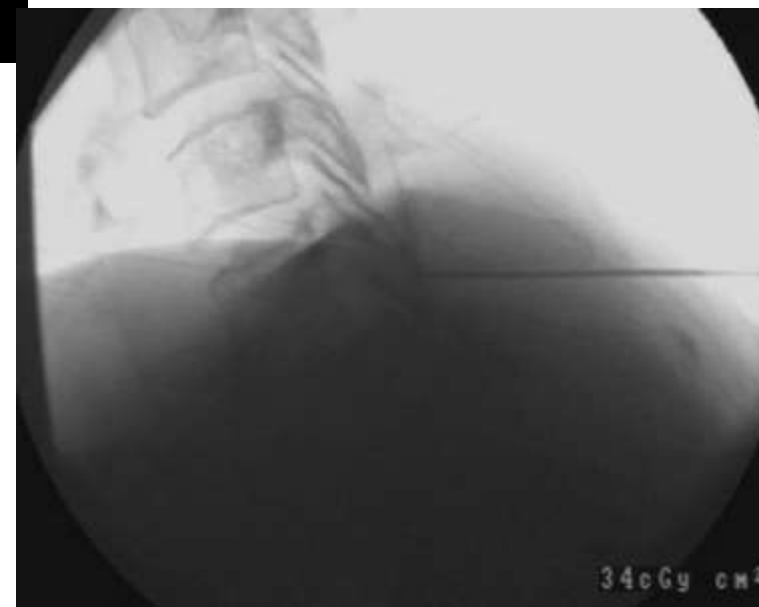
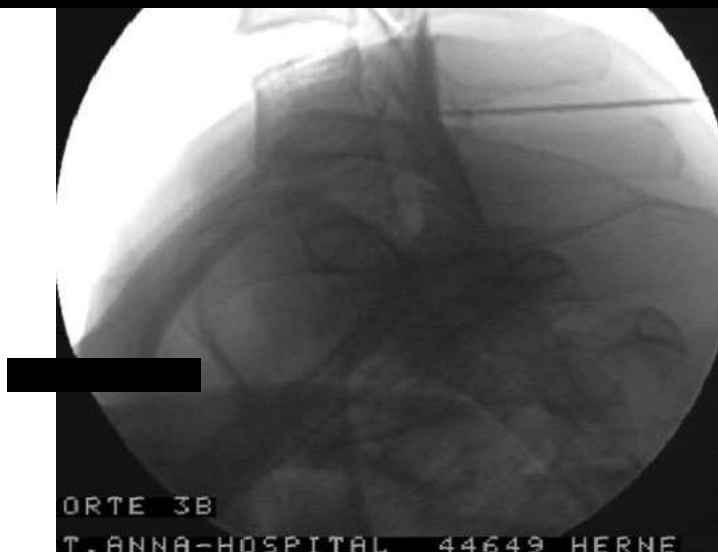
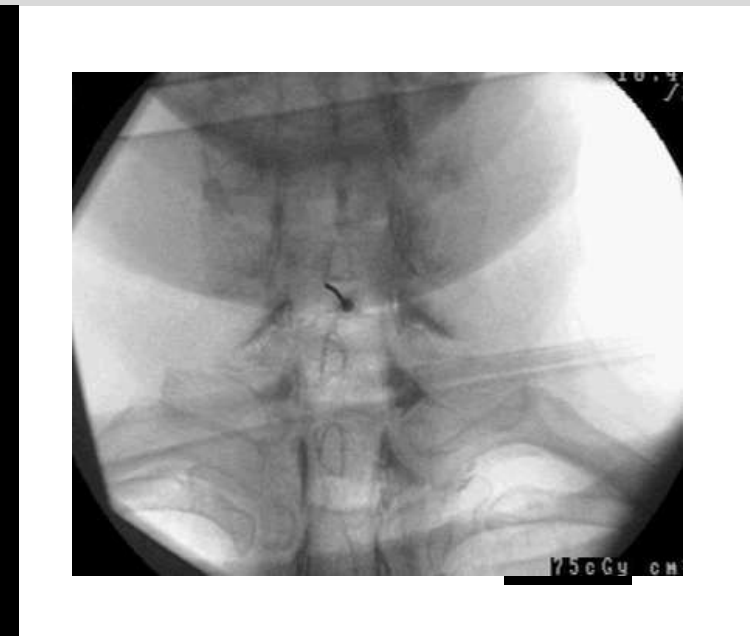
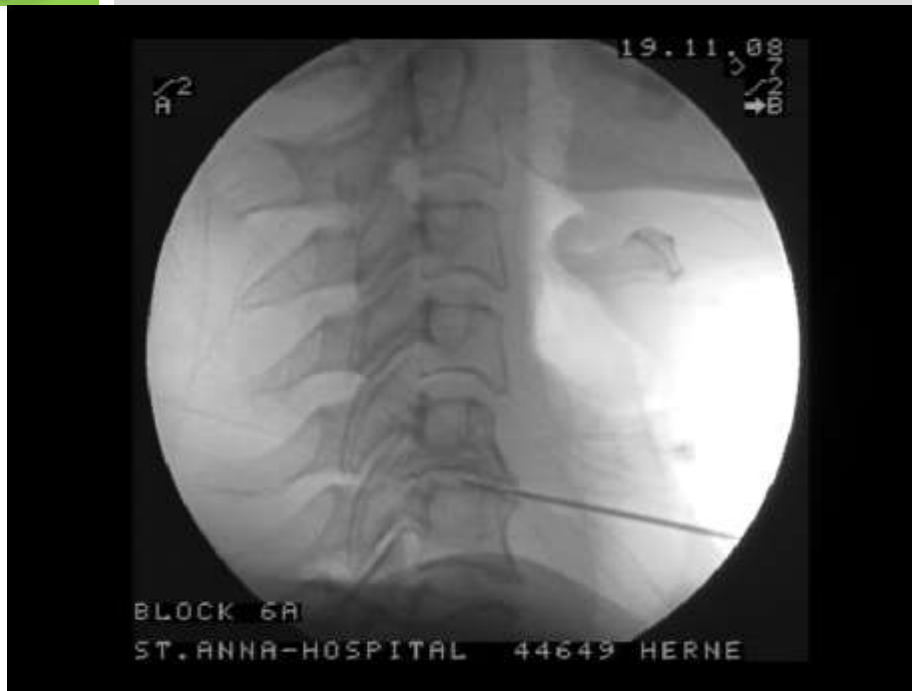dorsal

transforaminal

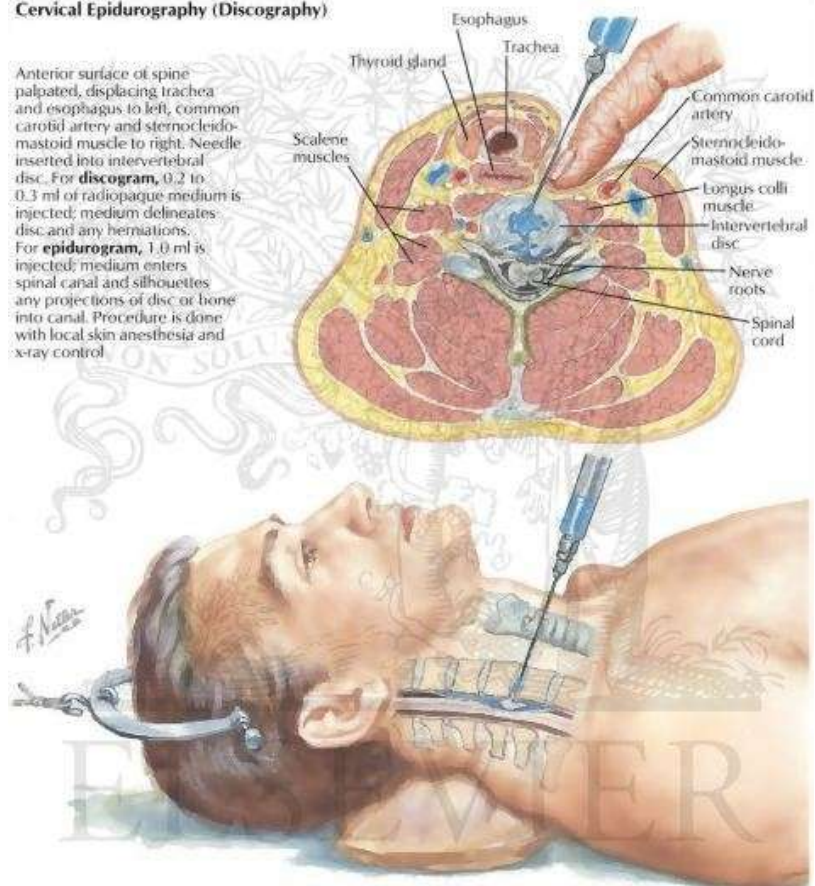
intradiscal





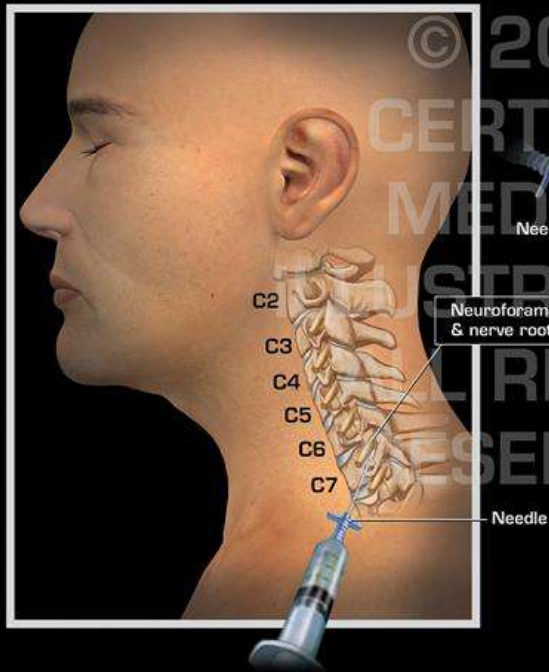
Cervical Epidurography (Discography)

Anterior surface of spine palpated, displacing trachea and esophagus to left, common carotid artery and sternocleidomastoid muscle to right. Needle inserted into intervertebral disc. For **discogram**, 0.2 to 0.3 ml of radiopaque medium is injected; medium delineates disc and any herniations. For **epidurogram**, 1.0 ml is injected; medium enters spinal canal and silhouettes any projections of disc or bone into canal. Procedure is done with local skin anesthesia and x-ray control.

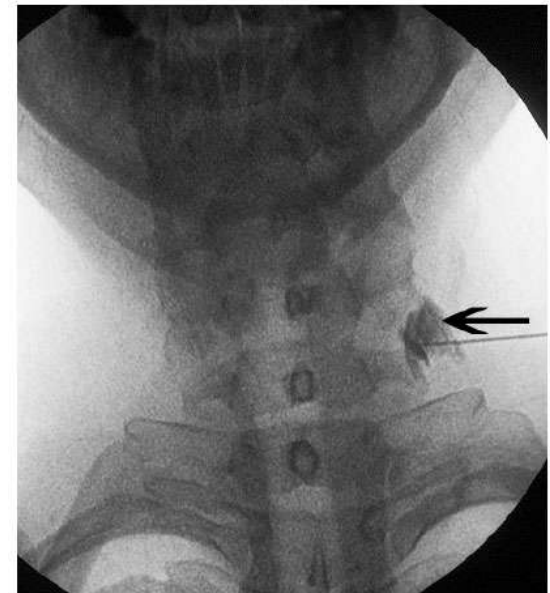
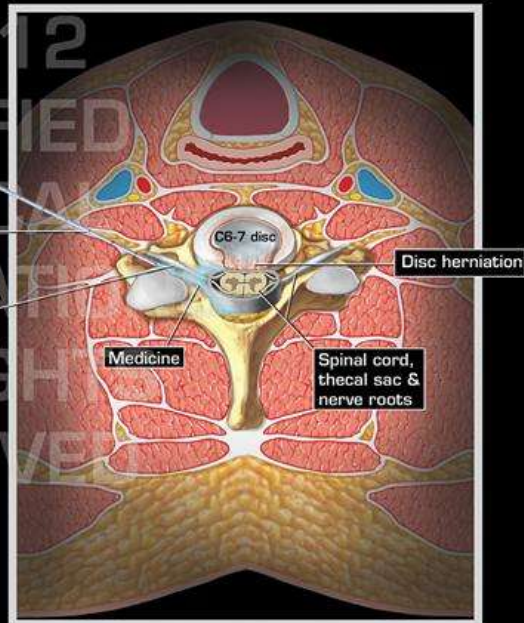


TRANSFORAMINAL EPIDURAL STEROID INJECTION OF CERVICAL SPINE

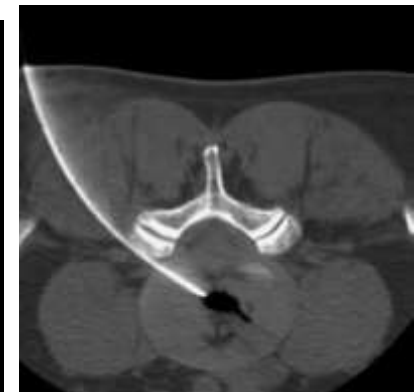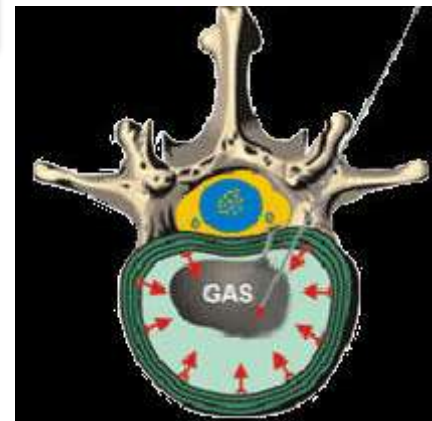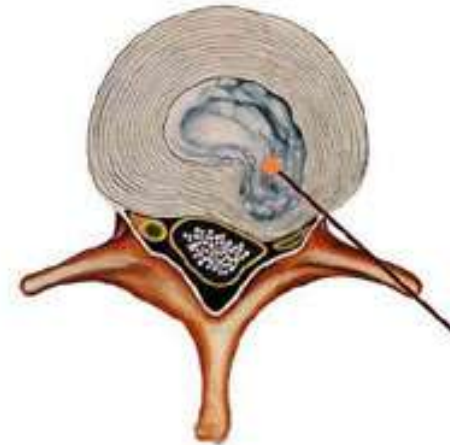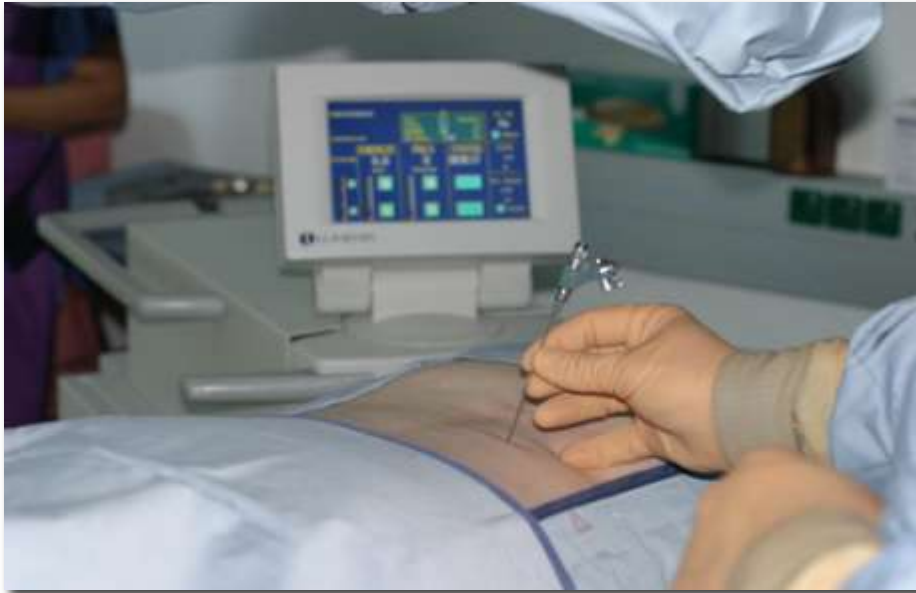A. Placement of Needle into Left (Right)
Neuroforamen at C6-7



B. Epidurogram & Injection of Steroid into
Epidural Space at Left (Right) C6-7,
Axial Section

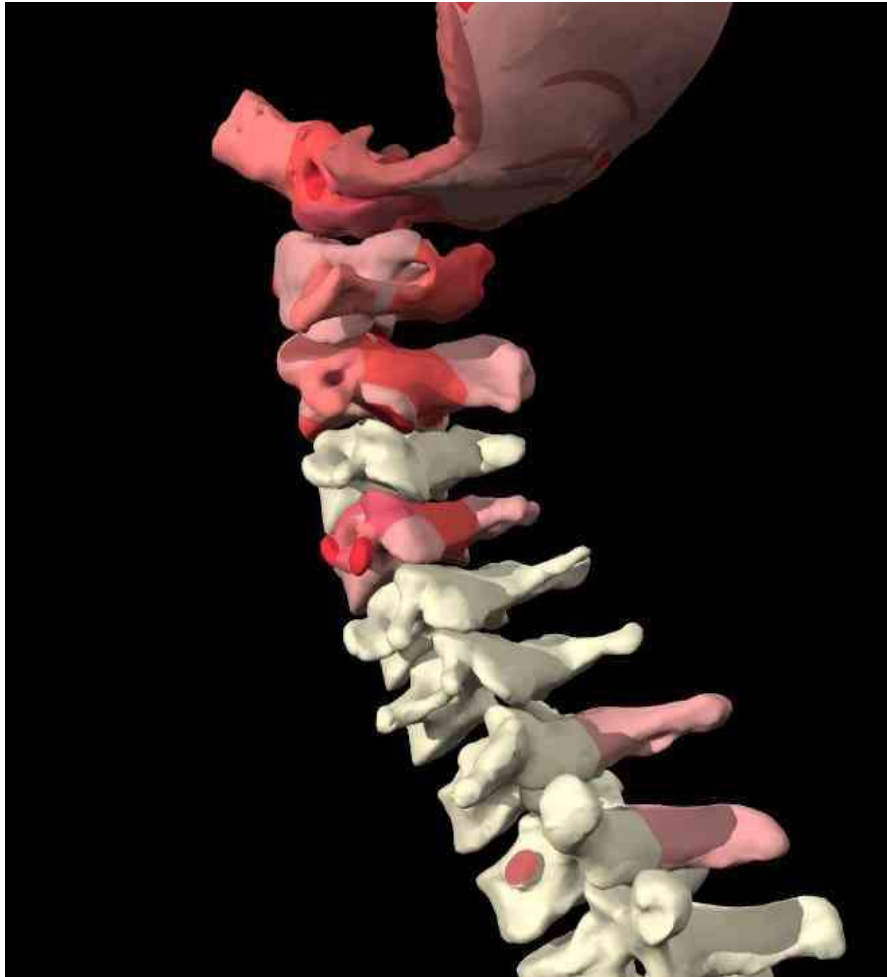


percutane laser disc decompression

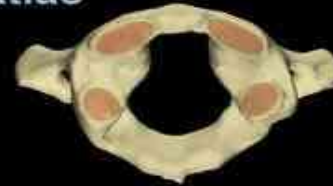



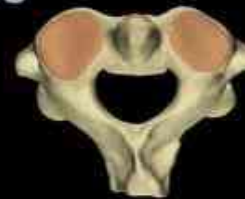Surgical treatment of degenerative diseases and injuries of the cervical spine



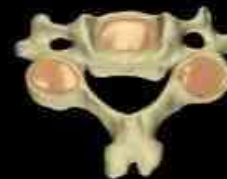Atlas



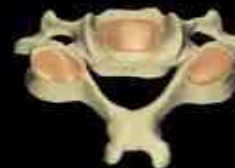Axis



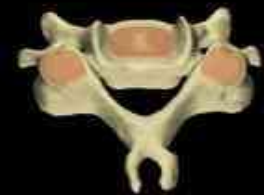C3



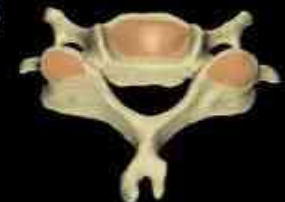C4



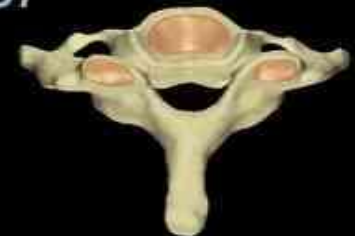C5



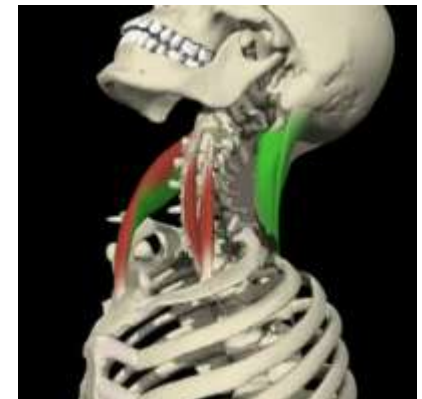
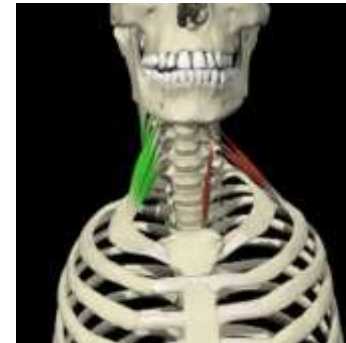
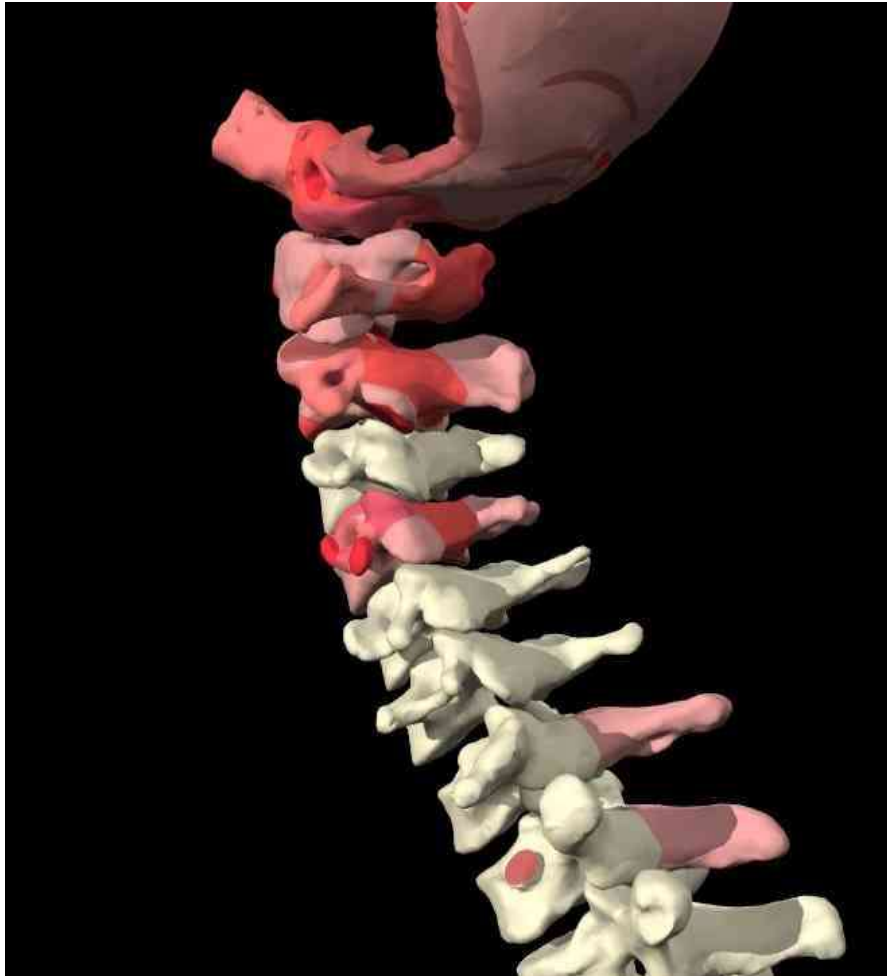
C6

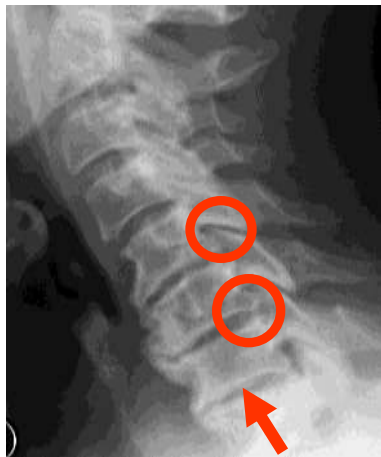


C7



ventral endoscopic nucleotomy

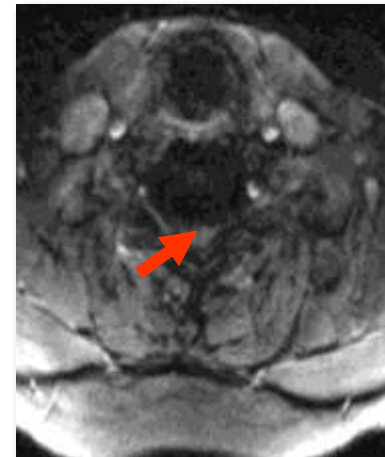




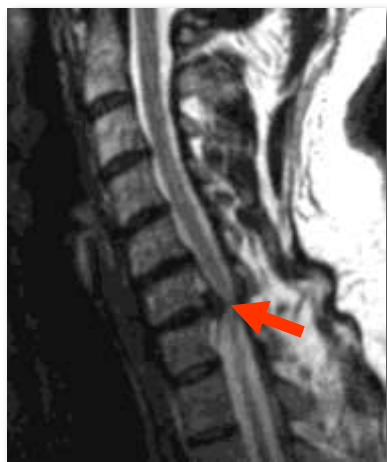Discusdegeneration

Osteophytes

Facette-Arthrosis



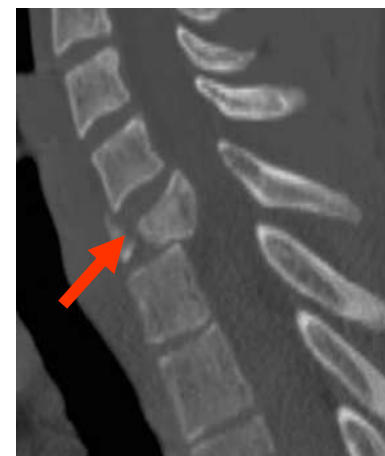SCS



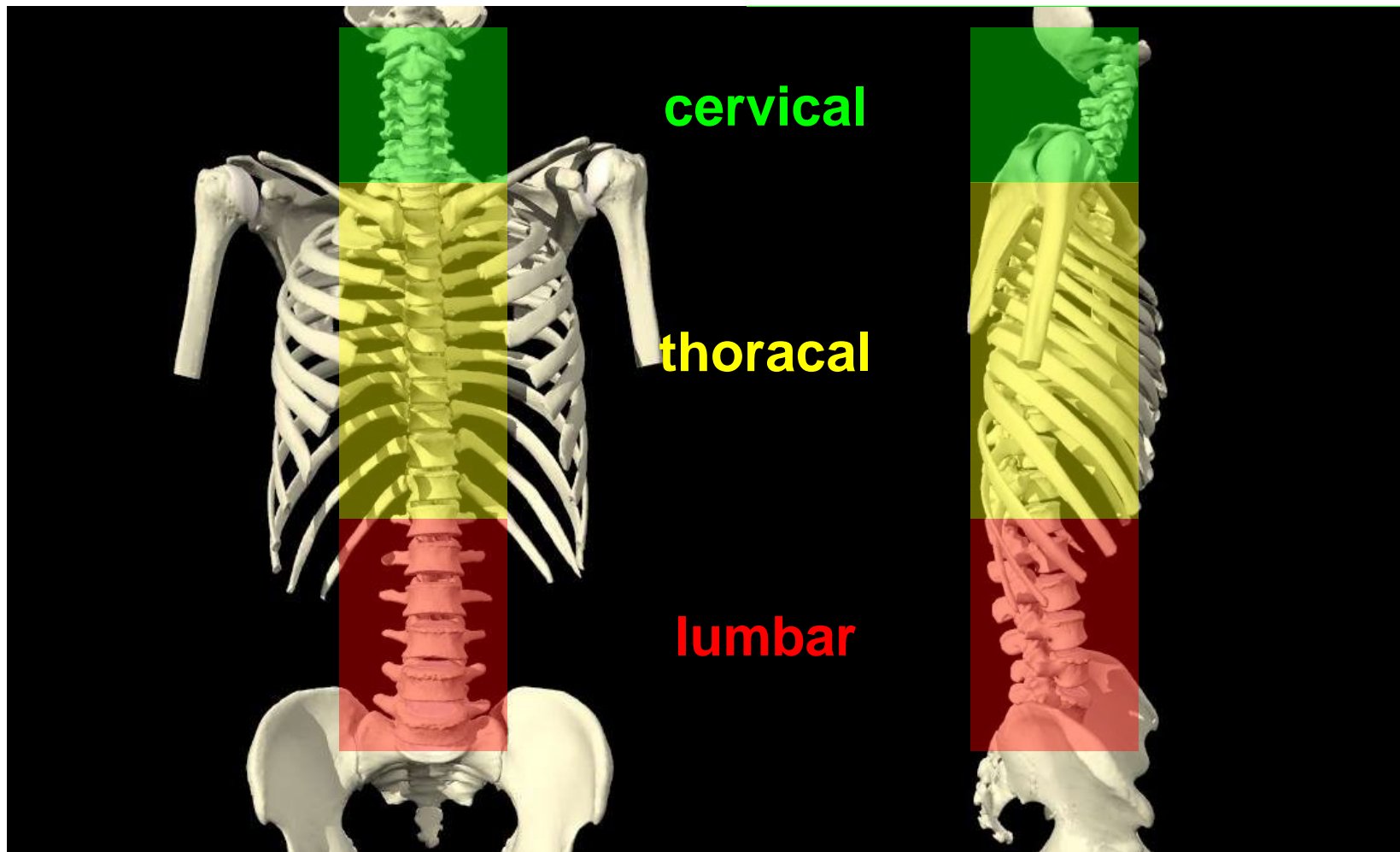
Herniations

Fracture



Inflammatory disease

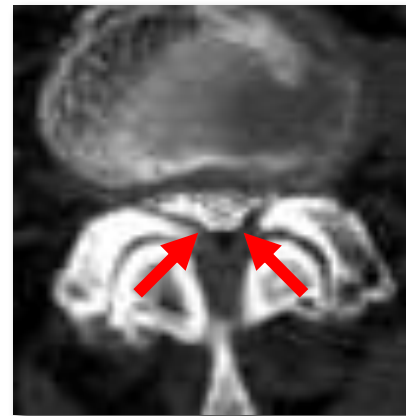
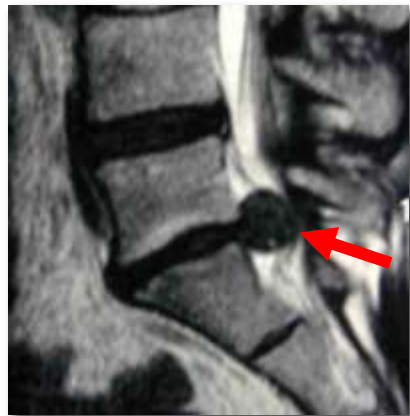
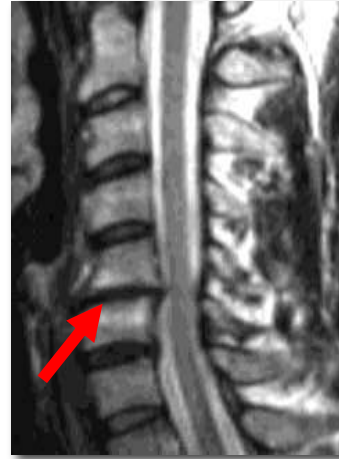
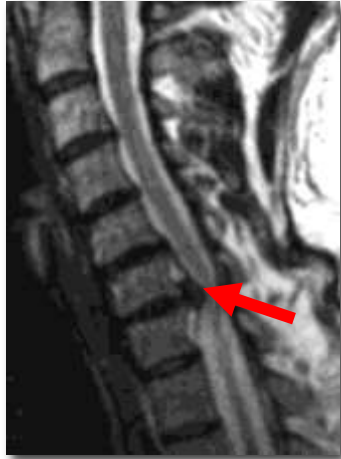Fullendoscopic operations



Fullendoscopic operations



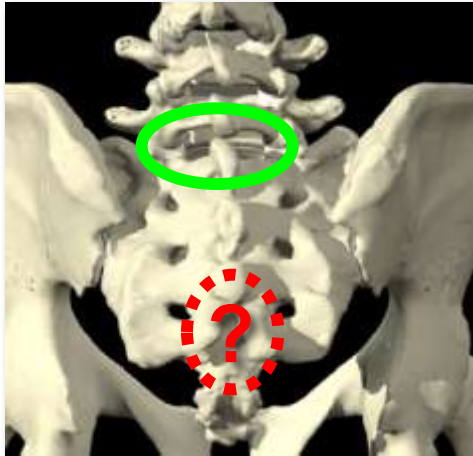


NPP

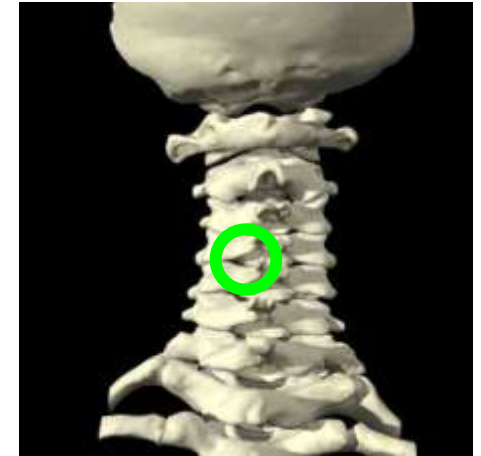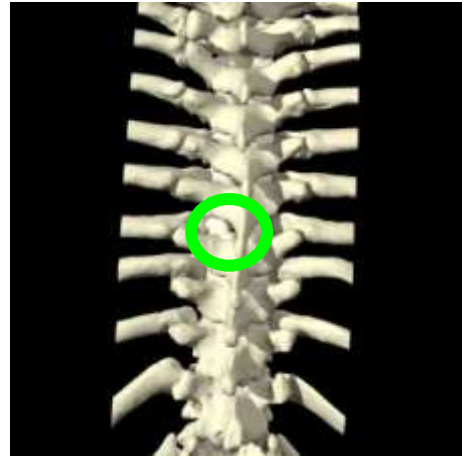
SCS

Radicular Symtoms

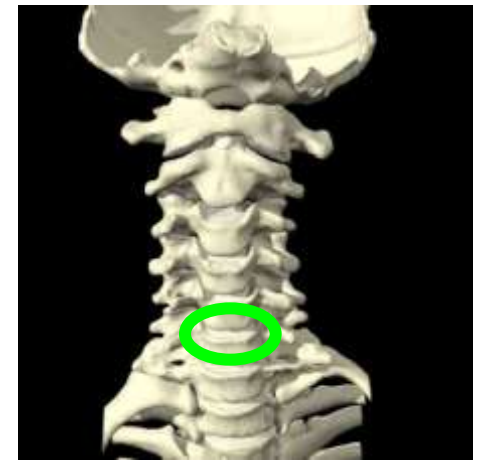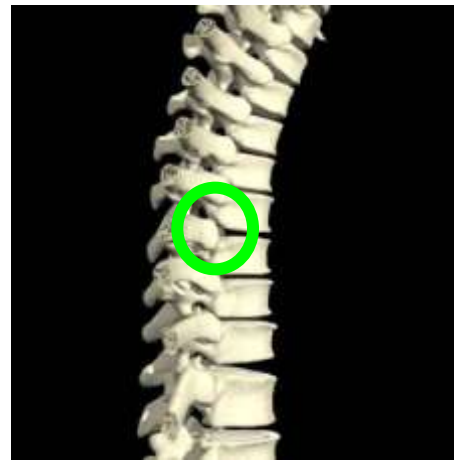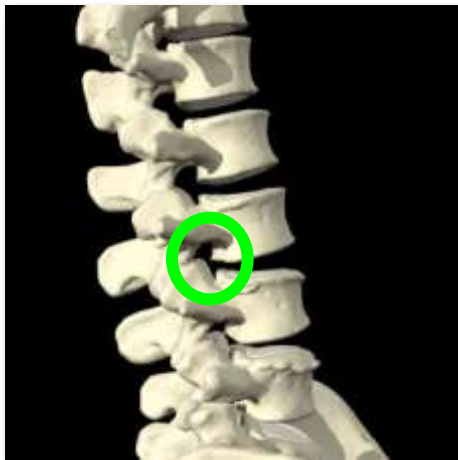Fullendoscopic operations



interlaminär

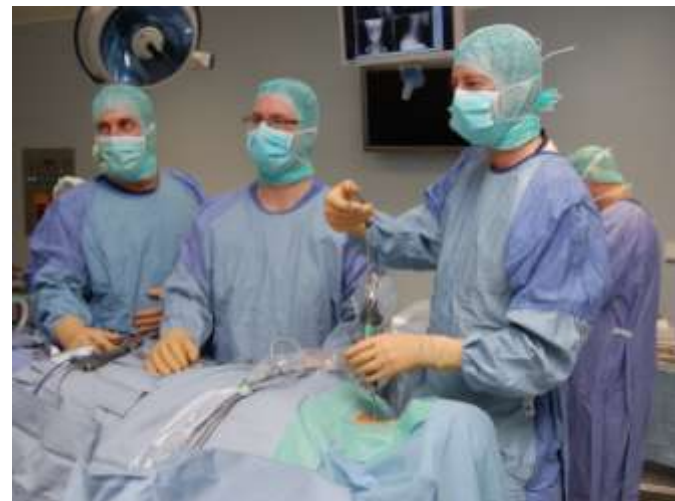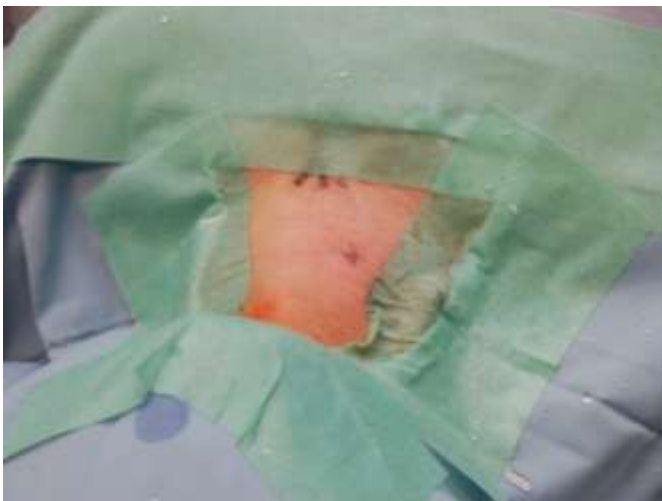
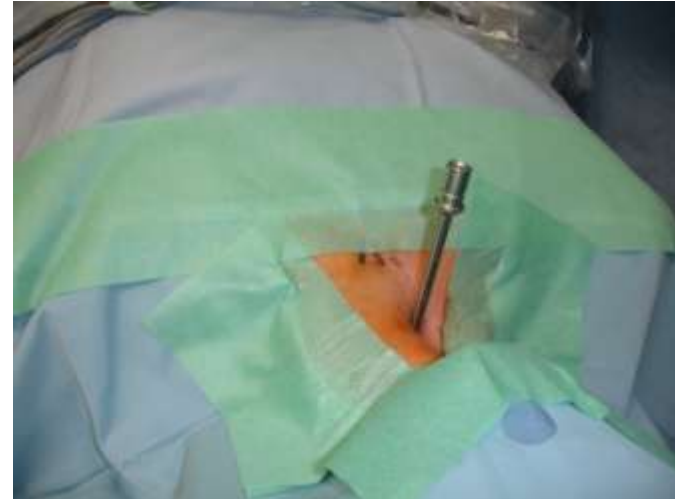

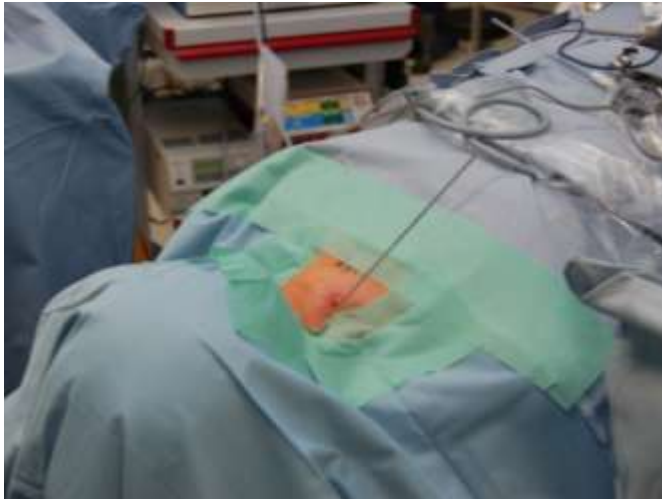

dorsal

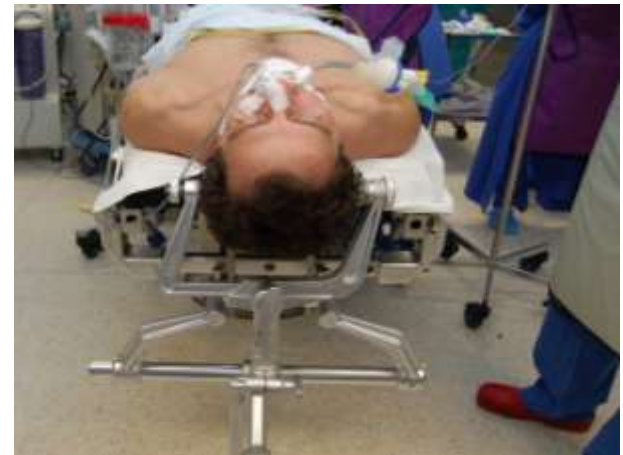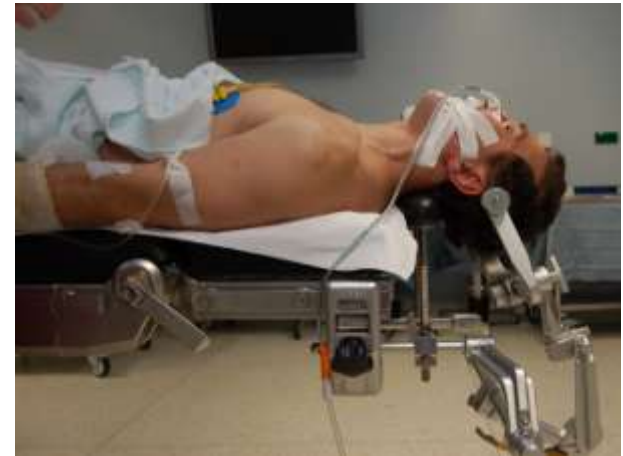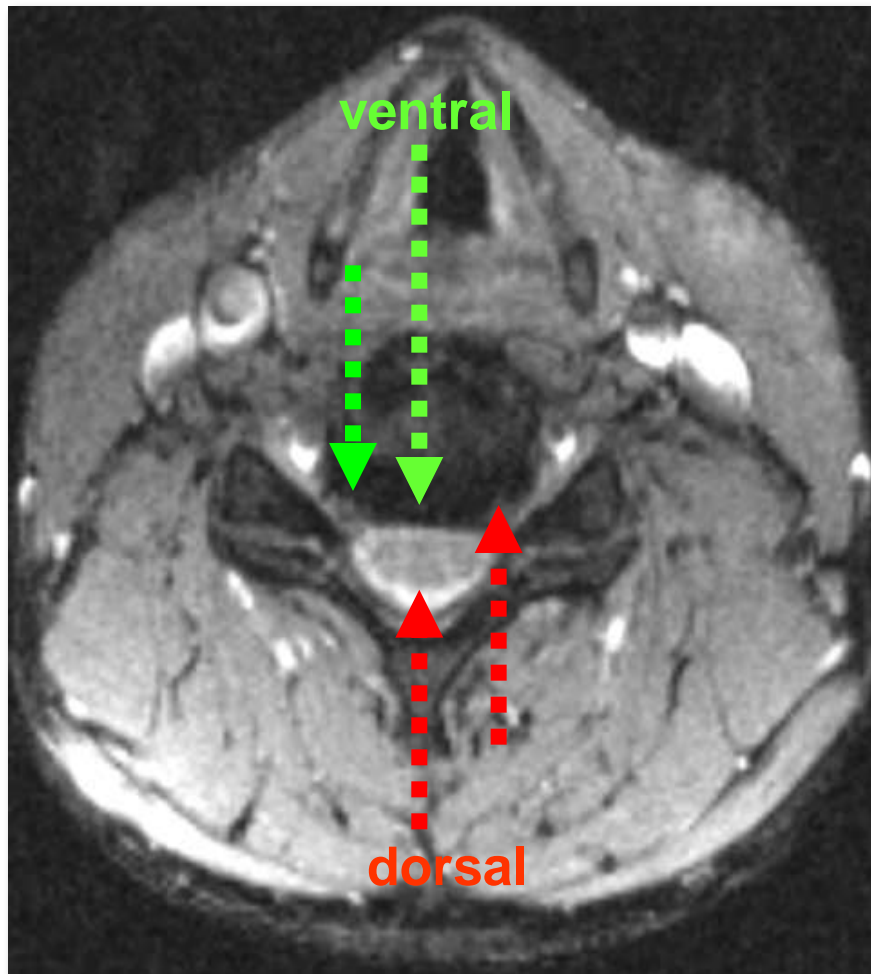


ventral

Fullendoscopic operations

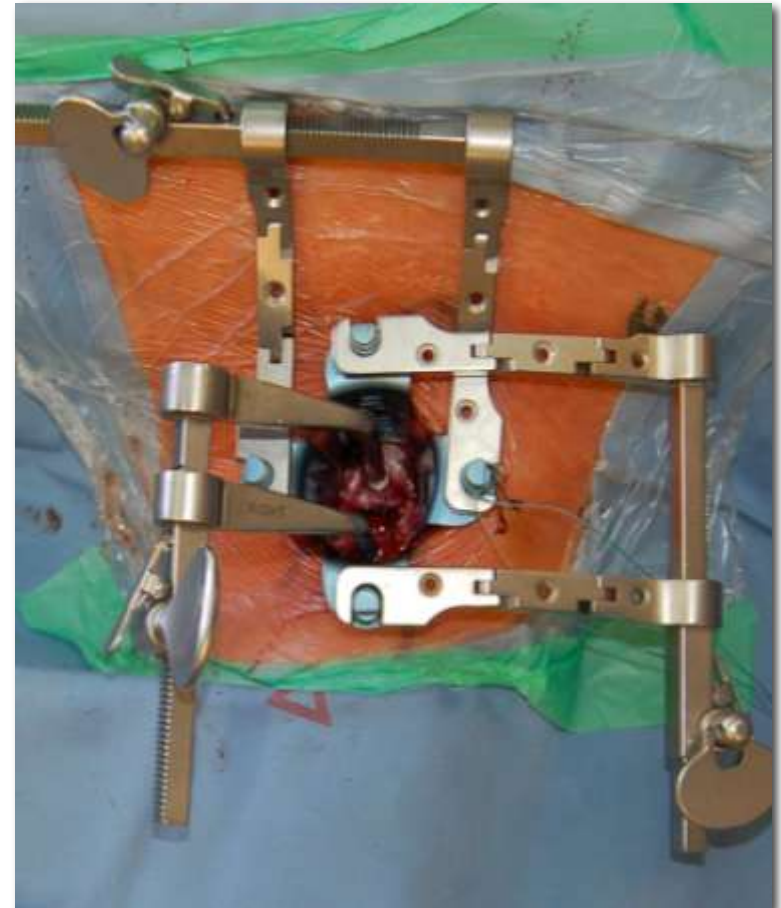
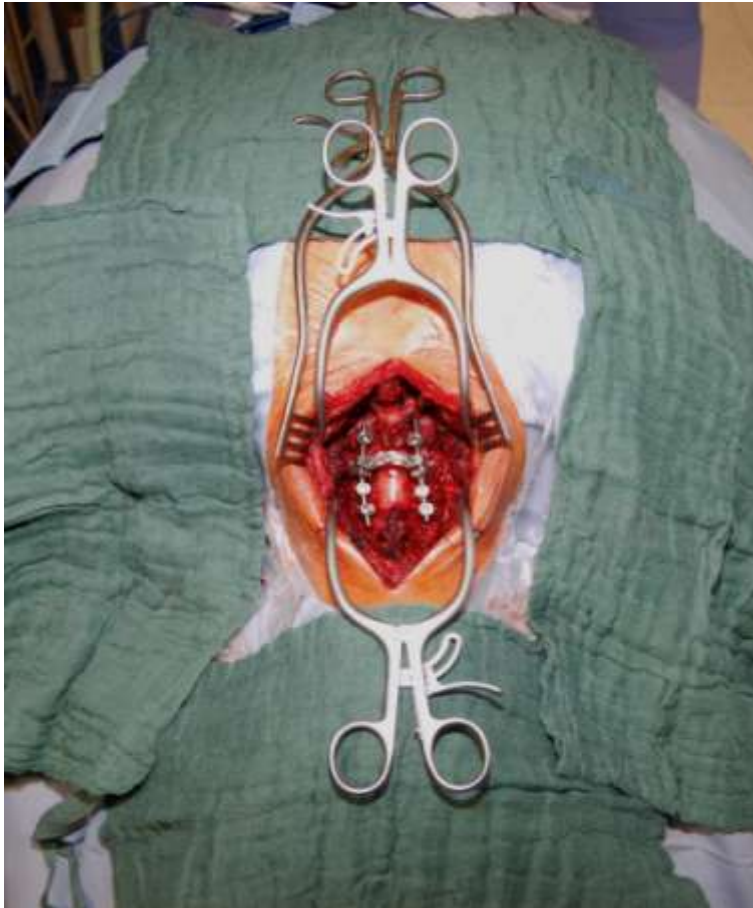


Open operation techniques



Open operation techniques

open operation dorsal/ventral

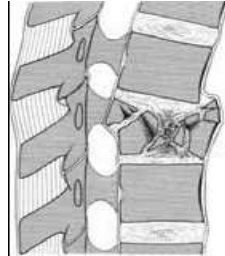
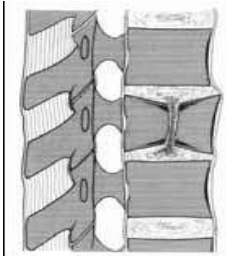
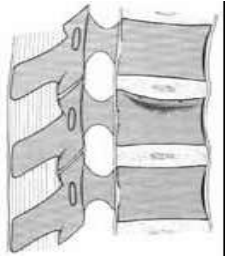


Fractures

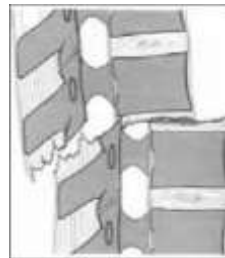
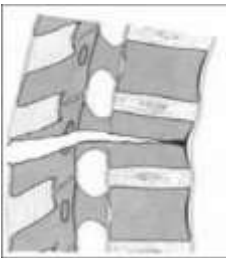
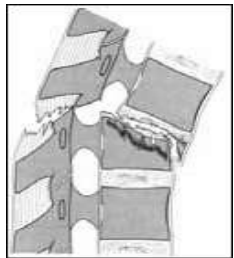


- car accidents
- young men
- high rate of collateral fractures

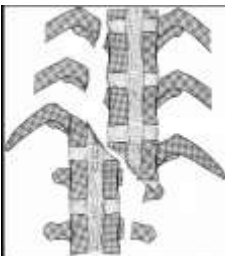
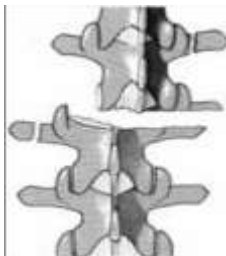
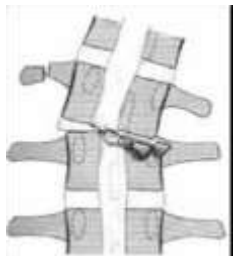
Fractures



Typ A : Compression fractures

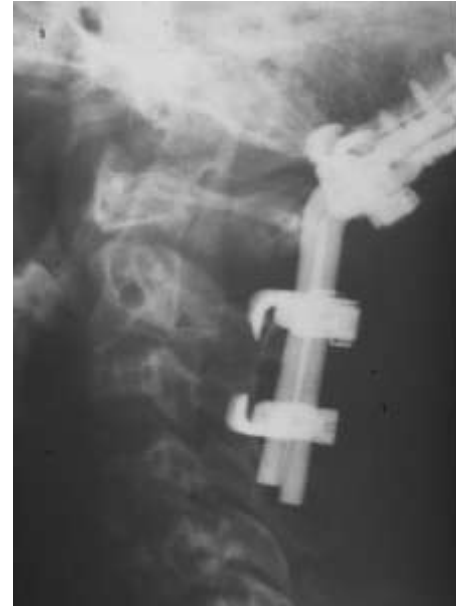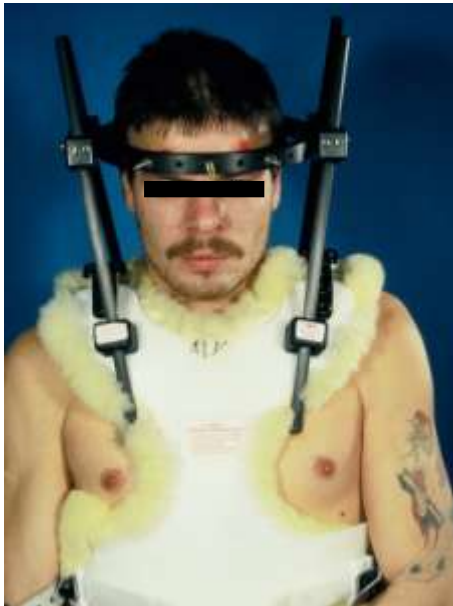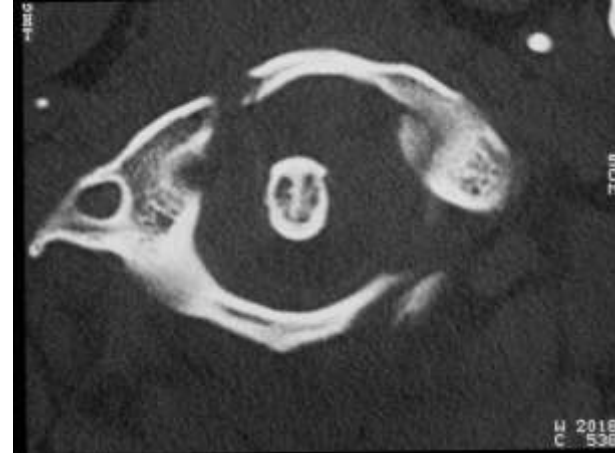


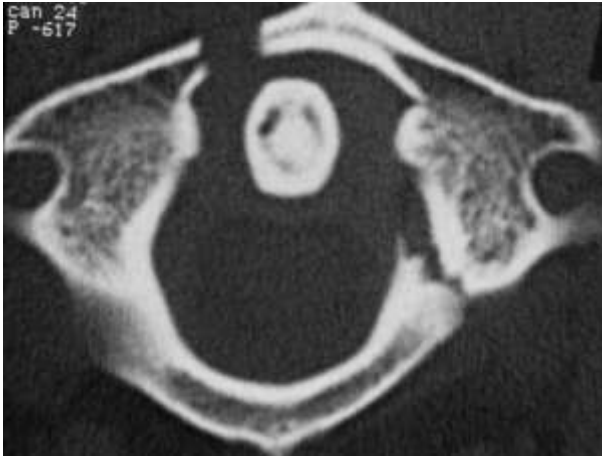Typ B : Distraction fractures

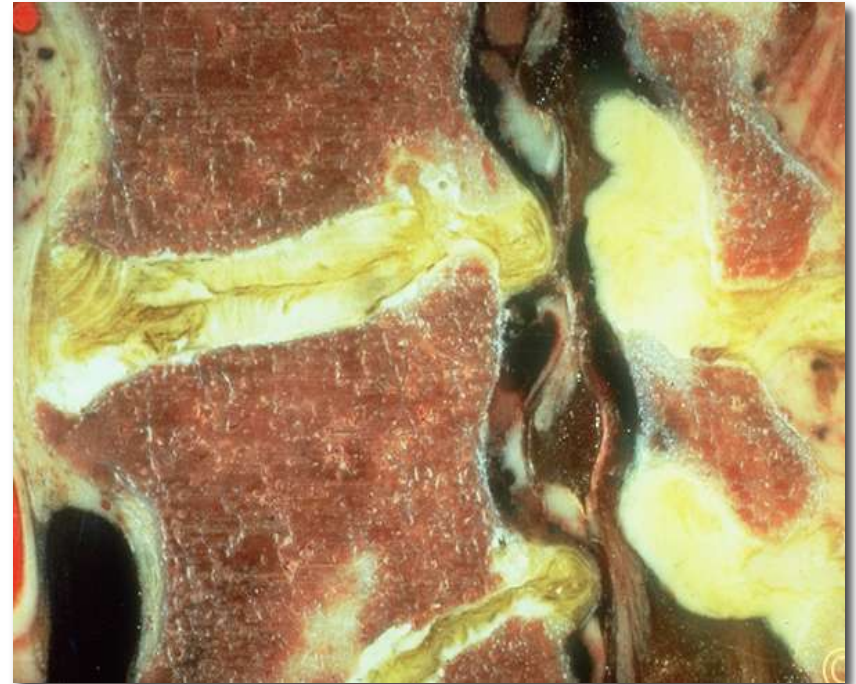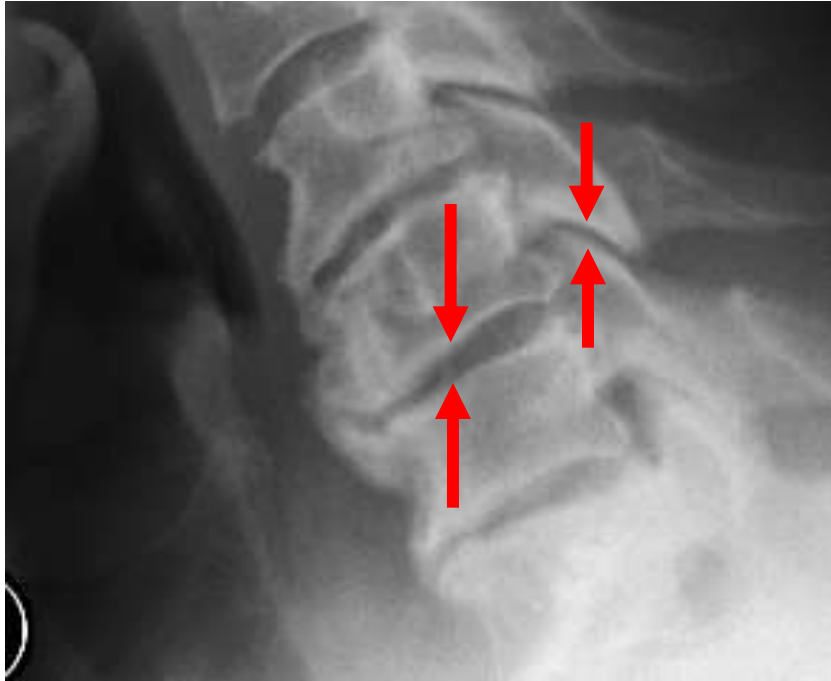


Typ C : Rotation fracture

Atlas fractures

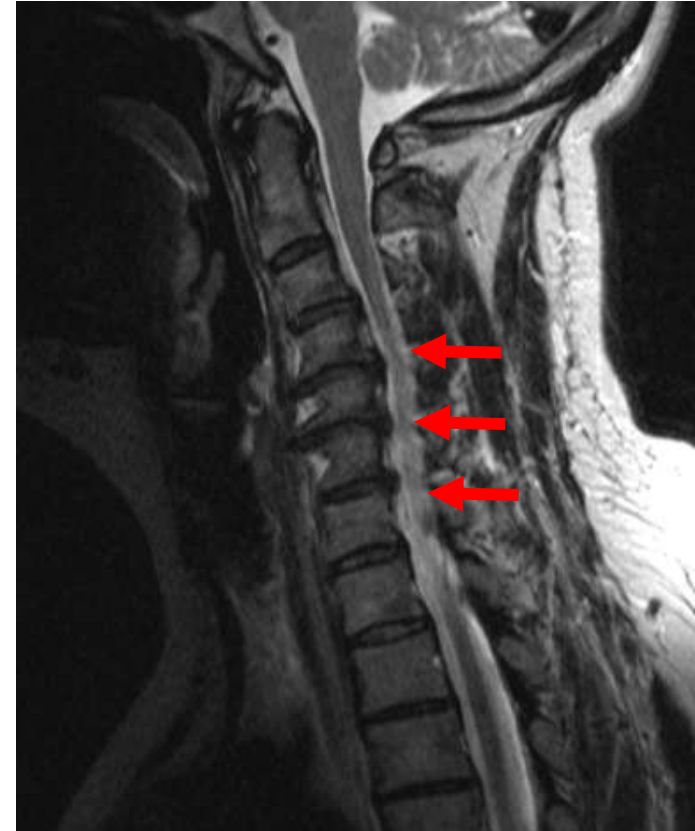
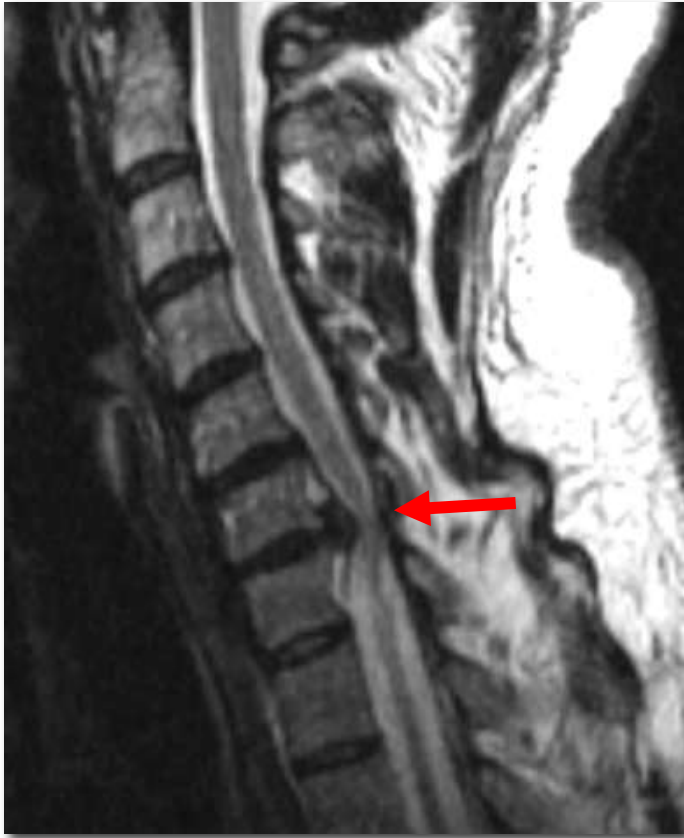
Degenerative disease



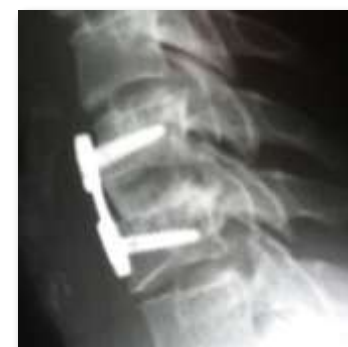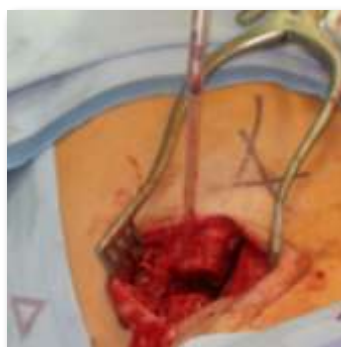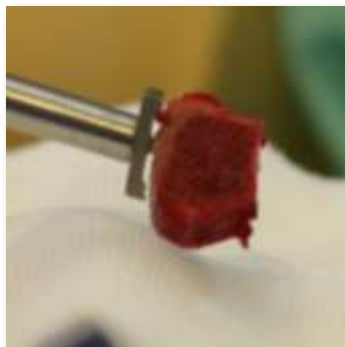


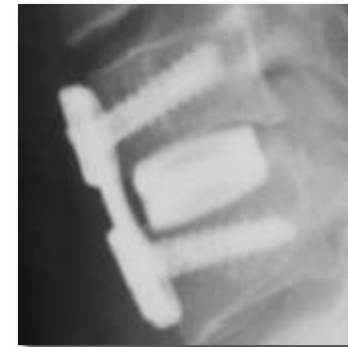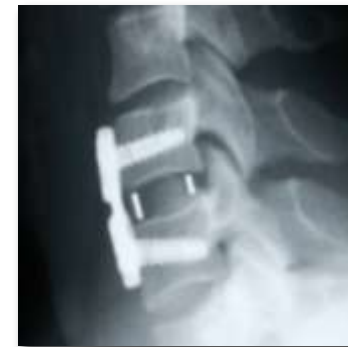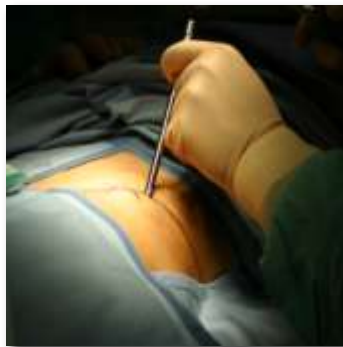- disc height reduction
- facet degeneration
- foraminal stenosis

Degenerative disease

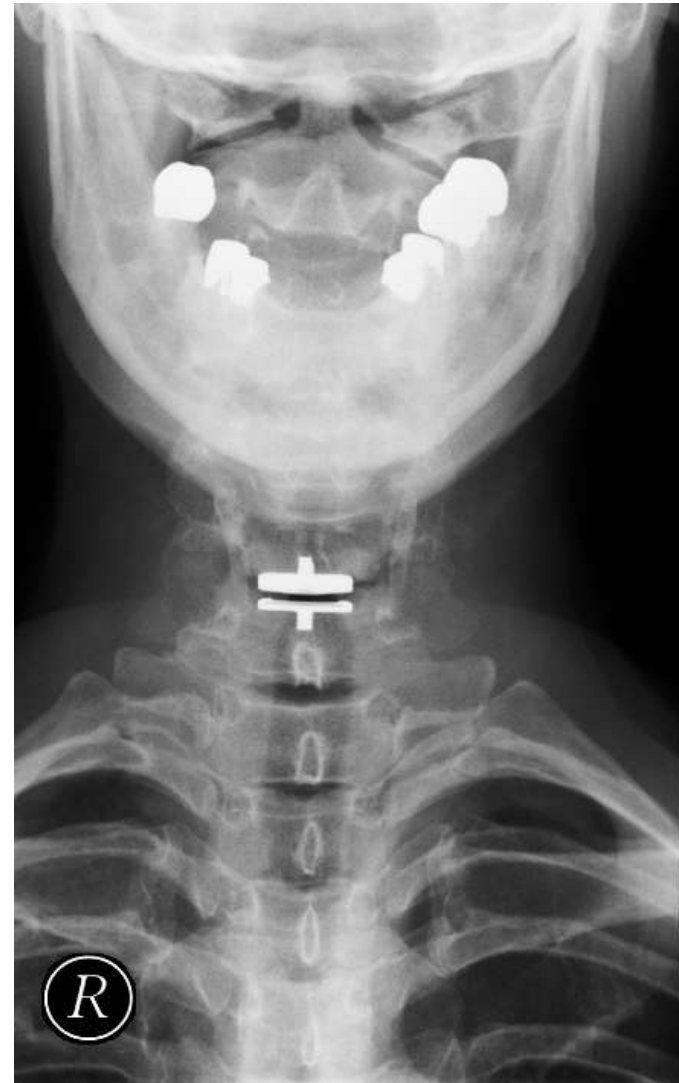
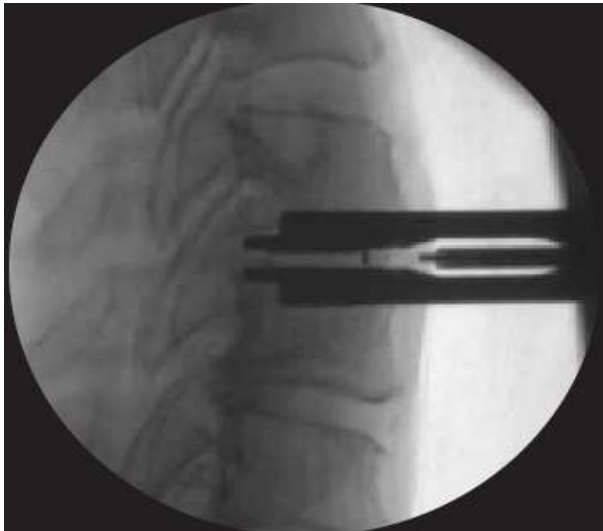
**NPP, spinal canal stenosis, myelon compression
pain, dysaesthesia, lost of strength**

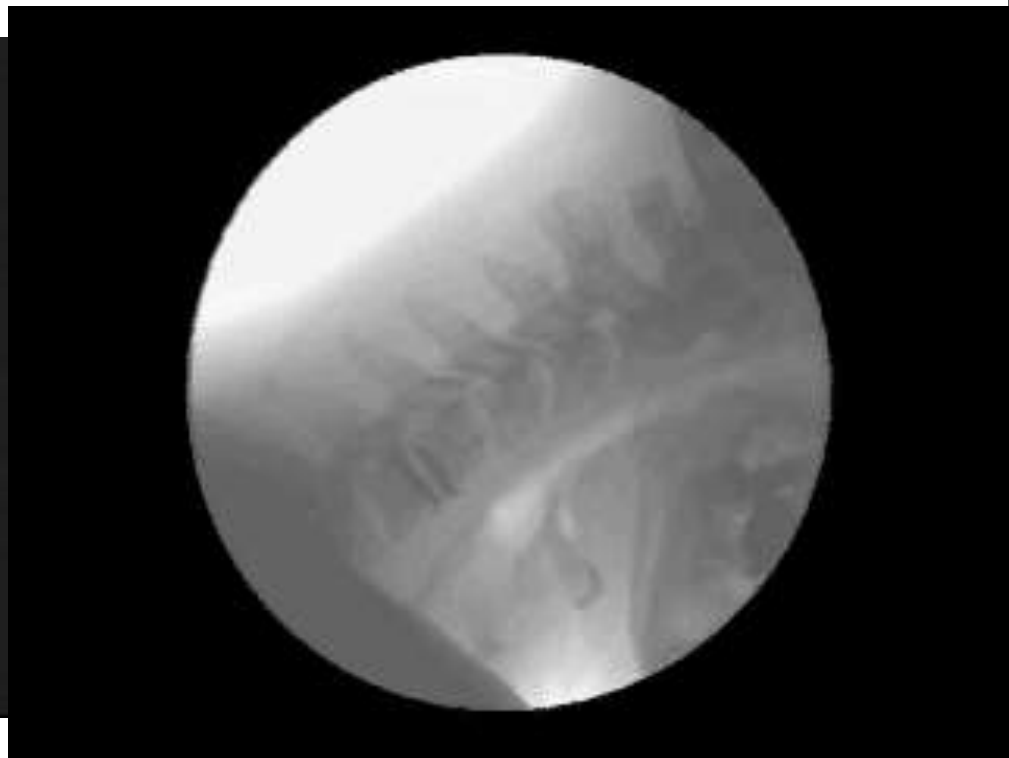
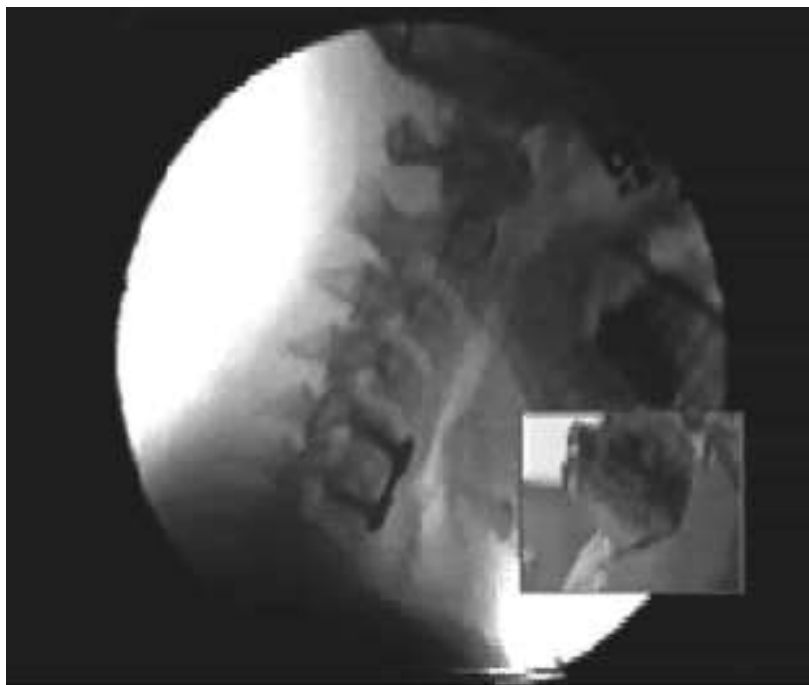Implants



Implants

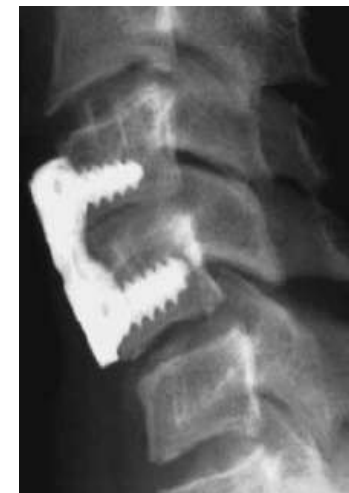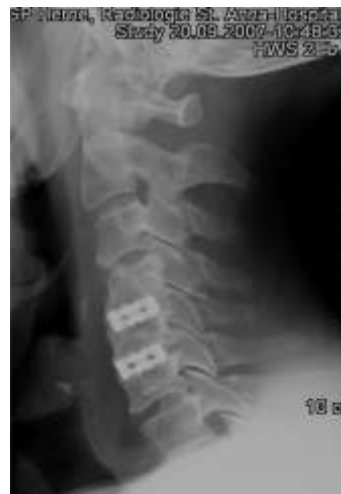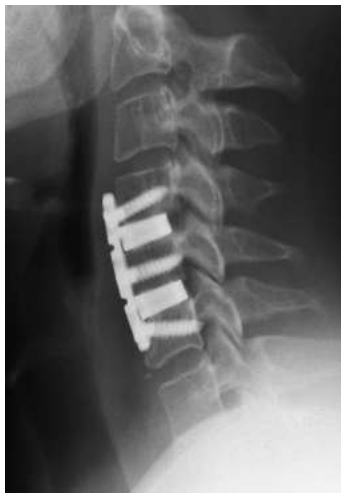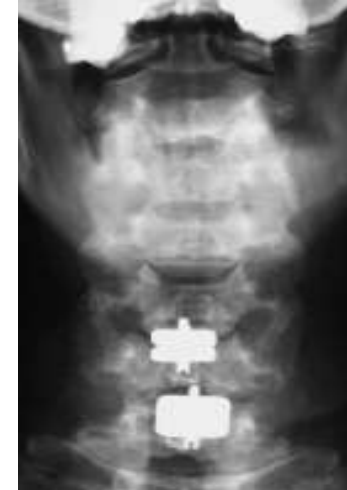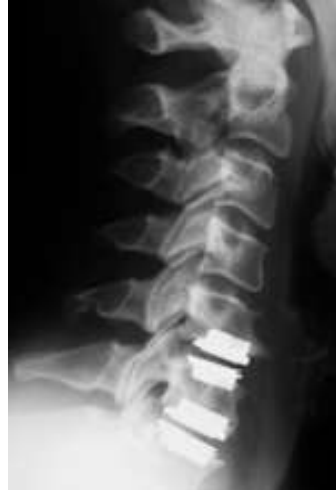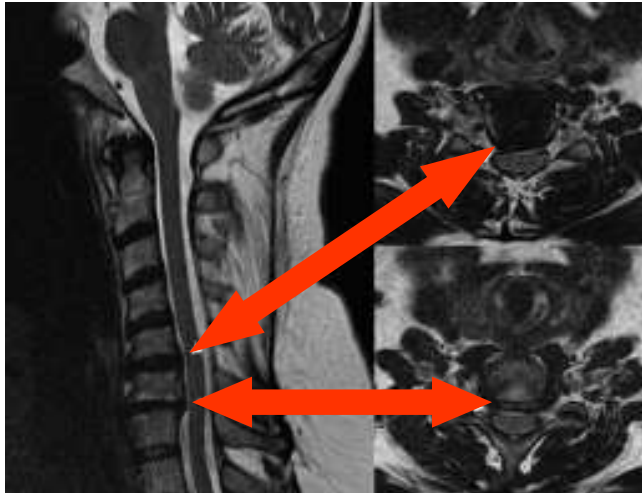


Degenerative disease

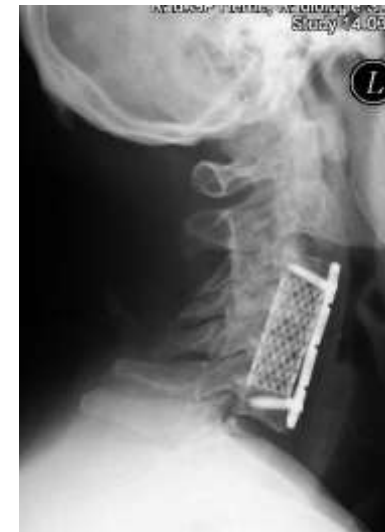
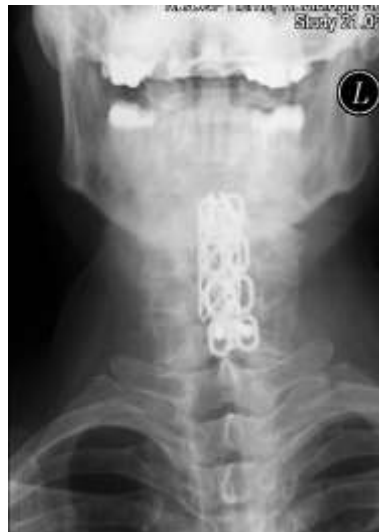
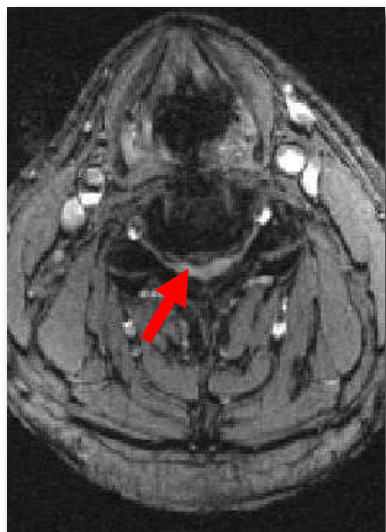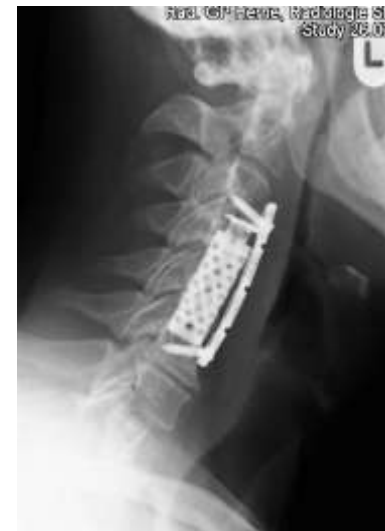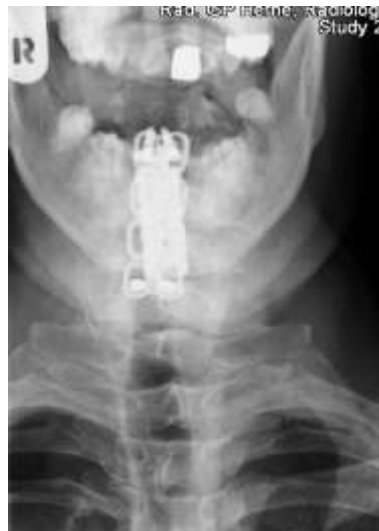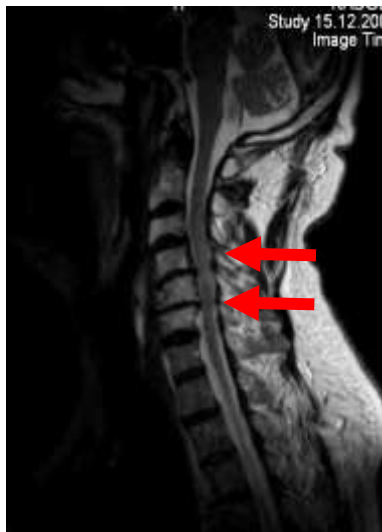artificial cervical disc

Degenerative disease



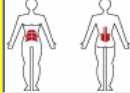



Degenerative disease

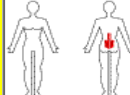







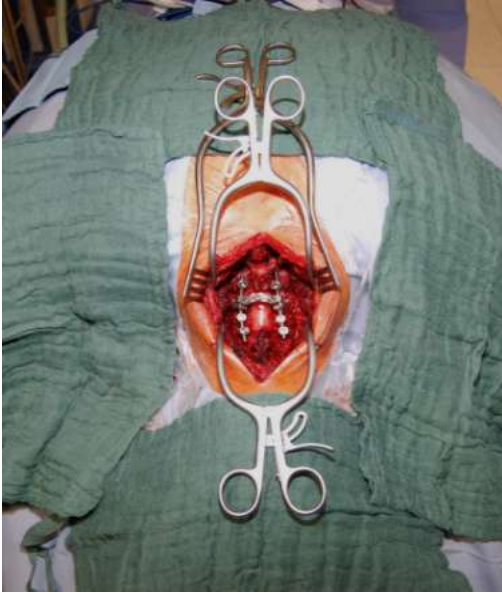
Physiotherapy after spine surgery

myoskelettal analysis

Muskelgruppe	isometr. Max. Kraft	Verän- derung in %	Dyn. Leist- ung	Kraftverhältnisse
Rücken 	AI 121 Nm	N/A		Bauch stärken 0,24 Rücken stärken 0,84 0,73
Bauch 	AI 88 Nm	N/A		Norm: 0,54
Drehung nach rechts 	AI 42 Nm	N/A		Links stärken 0,4 Rechts stärken 1,6 0,50
Drehung nach links 	AI 21 Nm	N/A		Norm: 1

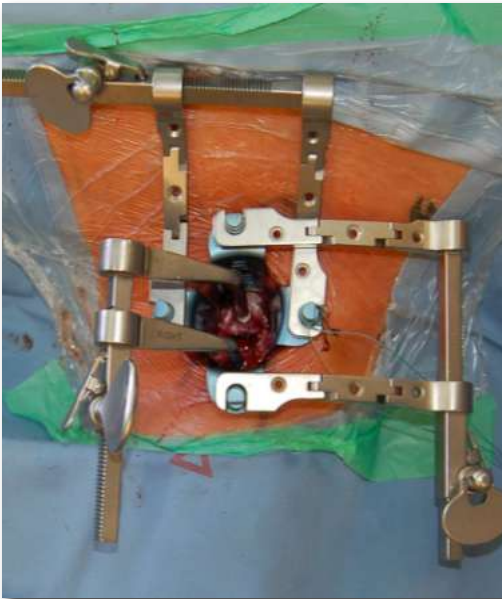
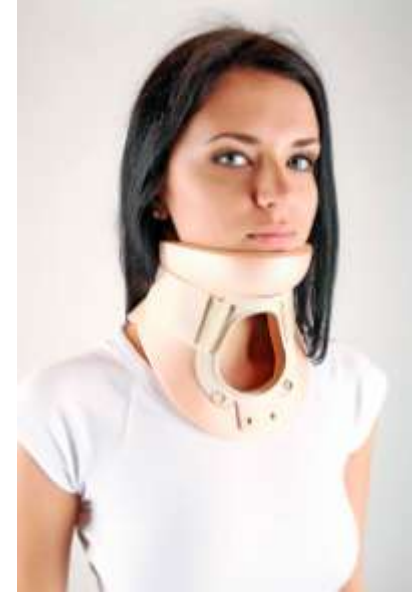Muskelgruppe	isometr. Max. Kraft	Kraft im Vergleich
Rücken 	AI 121 Nm	0% 200% 62%
Bauch 	AI 88 Nm	0% 200% 84%
Drehung nach links 	AI 21 Nm	0% 200% 26%
Drehung nach rechts 	AI 42 Nm	0% 200% 56%

Quelle der Referenzwerte: A. Denner - Muskuläre Profile der Wirbelsäule, Springer Verlag 1997



?

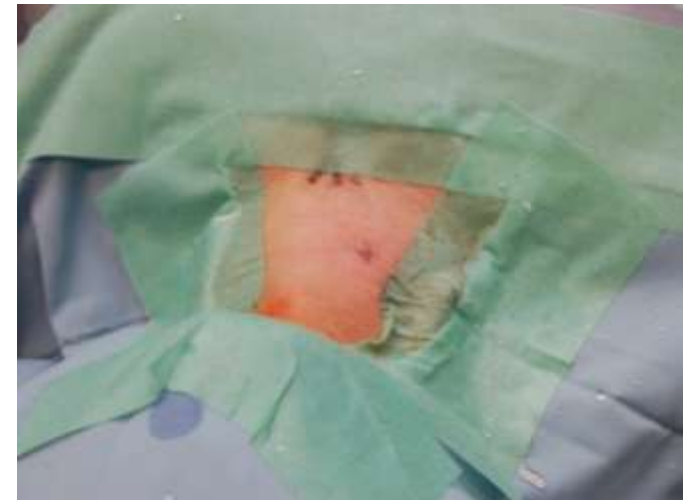
Ask the surgant



2 weeks



- **Early mobilisation**
- **Soft tissue protection**
- **Less post-operative pain**
- **Less scar tissue**
- **Less muscle damage**





3 phases of post-operative treatment

1. Supportive phase

2. Weaning phase

3. Rehabilitation phase



3 phases of post-operative treatment

1. Supportive phase

- Brace has to be worn all the time
- Can be taken off for body hygiene

2. Weaning phase

3. Rehabilitation phase



3 phases of post-operative treatment

1. Supportive phase

2. Weaning phase

- Brace can be taken off for some time
- Patient decides when brace will be taken off for longer periods

3. Rehabilitation phase



3 phases of post-operative treatment

1. Supportive phase

2. Weaning phase

3. Rehabilitation phase

- No brace needed



Patient management

- **Explain why brace is needed**
- **Explain handling with the brace**
- **Show patient how to behave**
- **Explain ADLs**
- **Try to support patient so he is not afraid**

Patient has to feel well informed

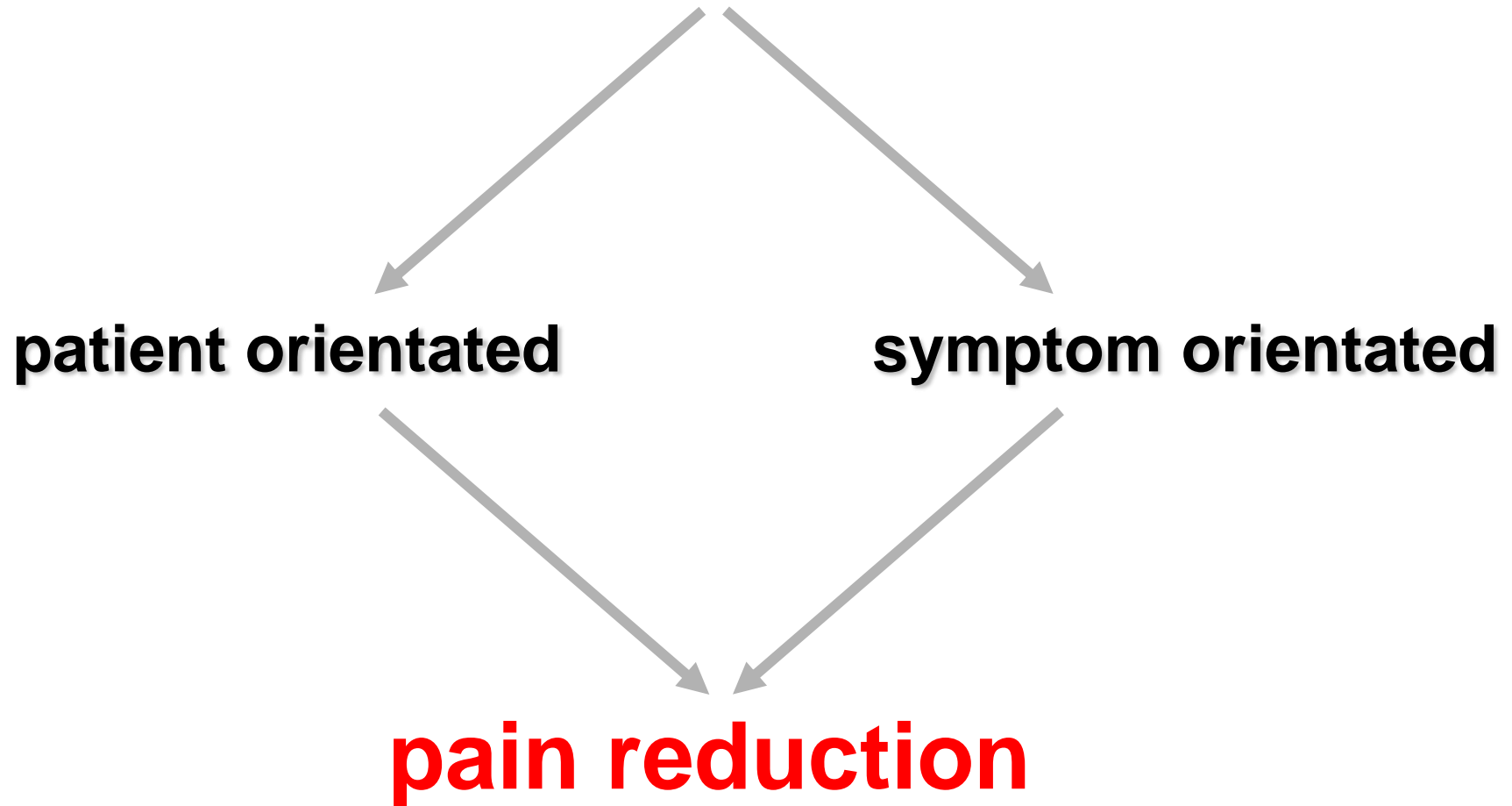


- brace can be taken off for showering etc.
- After MIS movement of neck is allowed
- Daily chores are allowed
- Heavy lifting is forbidden
- Extreme neck rotation is forbidden

Patient should listen to signals
His own body will tell him if he is behaving right

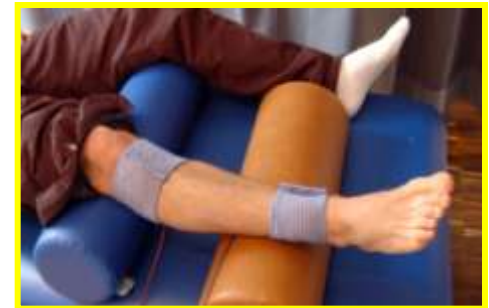
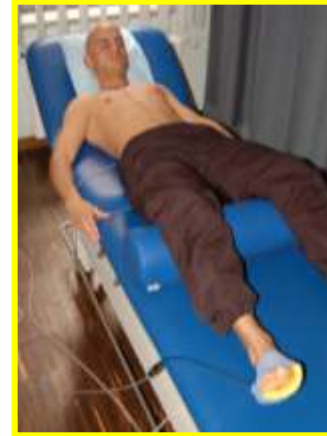
Individual therapy



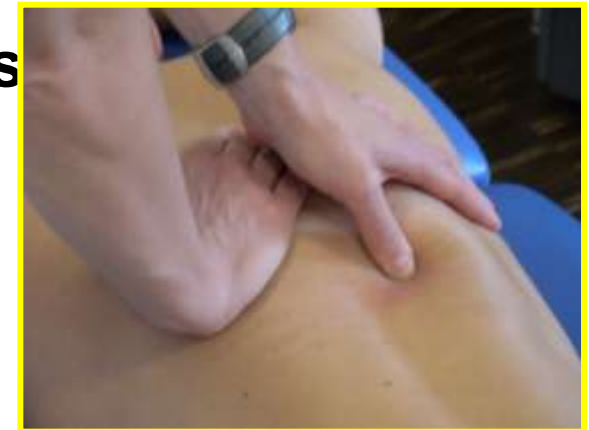physical therapy

- pain reduction
- muscle electrotherapy



Correction of pain avoiding posture

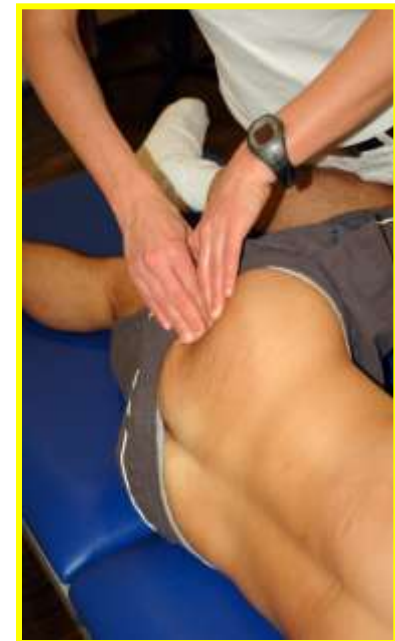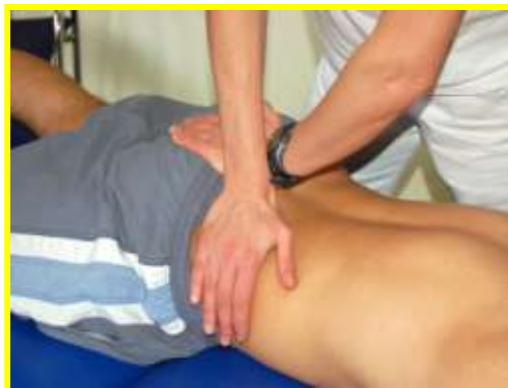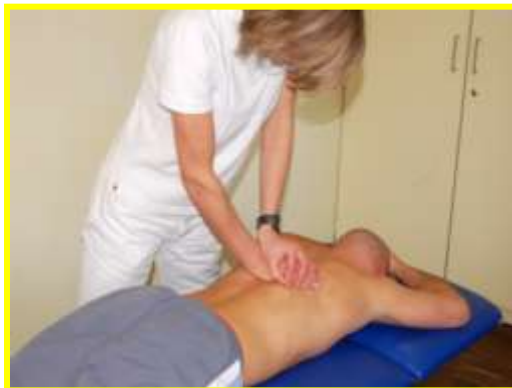- Massage of painful muscle groups
- stretching shortened muscles
- gait pattern correction




Scar tissue softening

Do not forget the rest of the spine

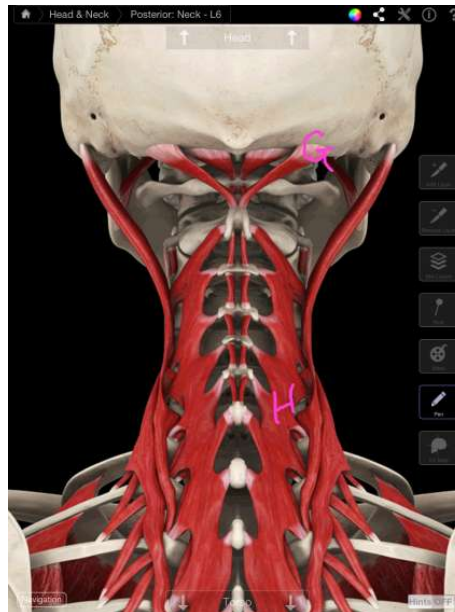
- thoracic/lumbar spine
- ileosacral joints
- M. Piriformis




Activation of segmental muscles of the spine

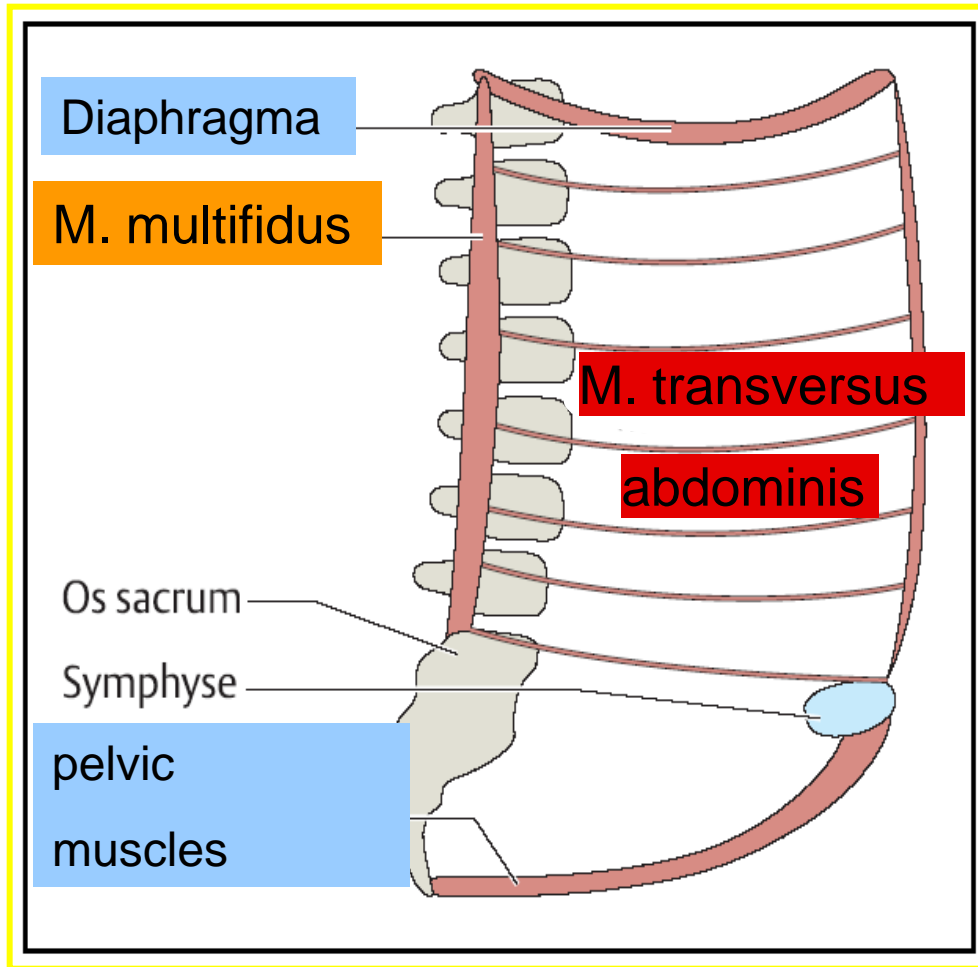


pain reduction



Characteristics

- **Monosegmental**
- **located at the dorsal aspect of the spine**
- **short lever arm \Rightarrow low torque**
 -  no movement generated**
- **axial stabilization of the facette joint:**
- **\Rightarrow spine stabilization**
 - \Rightarrow Motoric movement controll**




Active stabilization

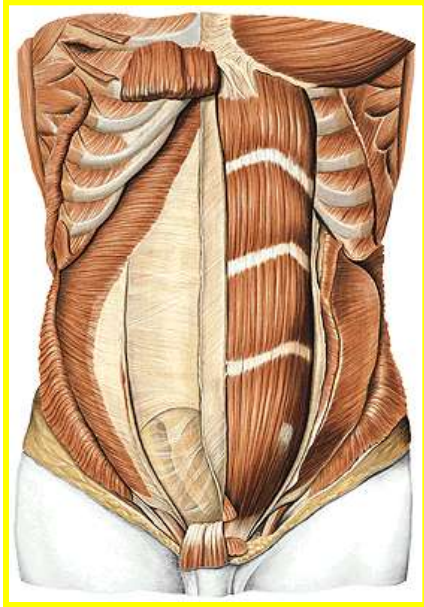
Stabilization of spine via abdominal pressure

Important to maintain intraabdominal pressure

At the cervical spine stabilization via segmental muscles

Characteristics

- polisegmental
- located at the dorsal and ventral aspect of the spine
- long lever arm \Rightarrow high torque 
cause movement
- no segment segmental stabilization



M. rectus abd.

M. obliquus abd. ext.

M. obliquus abd. int.

M. semispinalis

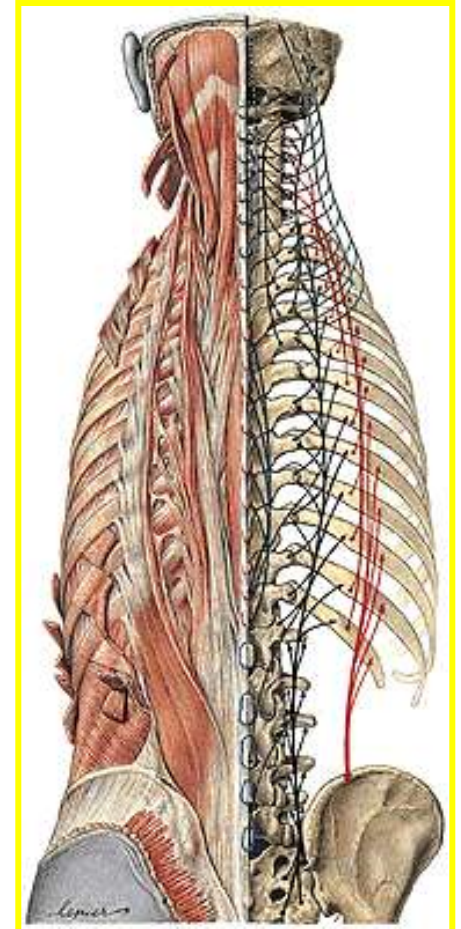
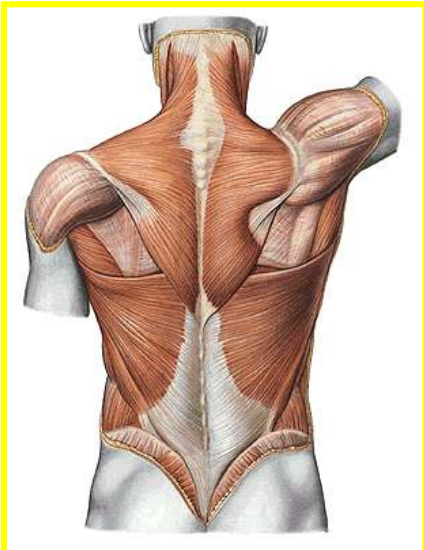
M. iliocostales

M. splenii

M. scaleni

M. latissimus dorsi

M. quadratum lumborum





Important for stable movement

ST. ELISABETH GRUPPE 
KATHOLISCHE KLINIKEN RHEIN-RUHR

**Segmental muscles have to be activated
before movement muscles.**

1. Activation of segmental muscles prior to movement

Segmental stability

2. Keeping segmental stability stable while activating movement muscles.

Global stability

3. Learning to use global stability in every day chores.

Functional stability

Supportive phase

Weaning phase


Rehabilitation phase

segmental stability

global stability

functional stability

pain while training:



insufficient segmental stability



















